

---

**INTERNATIONAL JOURNAL OF CURRENT RESEARCH IN  
BIOLOGY AND MEDICINE****ISSN: 2455-944X****www.darshanpublishers.com****Volume 1, Issue 3 – June- 2016**

---

**Original Research Article**SOI: <http://s-o-i.org/1.15/ijcrbm-2016-1-3-4>**Comparative Morphological and Histochemical Studies on Major Flight Muscles of Domestic Fowl (*Gallus gallus domesticus*), Guinea Fowl (*Numida maleagris*) and Pigeon (*Columba livia domesticus*)****Danmaigoro A.\*<sup>1</sup>, Shehu, S.A.<sup>1</sup>, Habibu, H.<sup>1</sup>, Hena, S. A.<sup>1</sup>, Mahmud, M. A.<sup>2</sup>, Bello, A.<sup>1</sup>**<sup>1</sup>Department of Veterinary Anatomy, Usmanu Danfodiyo University, Sokoto<sup>2</sup>Department of Animal Health and Production Technology, Niger State College of Agriculture, Mokwa, Niger State, Nigeria

\*Corresponding Author

---

**Abstract**

Gross morphology, gross morphometry, histology and histochemistry of major flight muscles in domestic fowl, guinea fowl and pigeon were conducted on fifteen birds (five birds each; domestic fowl, guinea fowl and pigeon) obtained from Sokoto metropolitan market. The birds were weighed, dissected and eviscerated after which the comparative gross anatomy and histological studies were carried out. The length, width and weight of the major flight muscles were measured using ruler, measuring tape and weighing balance respectively. Tissue samples were taken from the middle parts of the pectoralis and supracoracoideus muscles. After fixation in Bouin's solution, sections were prepared using routine histological techniques. Tissue samples were stained using Hematoxylin and Eosin (H&E) and Periodic Acid Schiff (PAS). Results showed that the mean weight, mean length and mean width of the pectoralis muscle in domestic fowl were 40.12±3.25g, 15.25±0.32cm and 6.32±0.11cm respectively. In guinea fowl they were 83.37±4.73g, 16.45±0.16cm and 8.67±0.11cm respectively while in pigeon they were 23.25±1.30g, 9.5±0.025cm and 5.55±0.02cm respectively. The relative indexes of the pectoralis muscle were 6%, 13% and 18% in domestic fowl, guinea fowl and pigeon respectively. While the total flight muscle mass were 70%, 77% and 84% in domestic fowl, guinea fowl and pigeon respectively. It was concluded that since 21.6% of the pigeon weight was breast muscle, it indicated that the pigeon is a powerful flier. Also, since 8.6% of the domestic fowl weight was the breast muscle; it indicated that the domestic fowl is not a powerful flier.

**Keywords:** Anatomy, Flight muscles, birds.

---

**Introduction**

Poultry refers to all domesticated birds kept for egg or meat production and these include chicken, turkey, ducks, pigeon, guinea fowl, and geese (Komolafe *et al.*, 1979). Poultry meat in Nigeria has been one of the sources of animal protein to the over-growing Nigerian population, making significant contribution to human nutrition and economic development (Michael *et al.*, 1992). Birds also serve as experimental animals, house hold pets and as a major source of animal protein (Ojo, 1990). Studies on flight

muscles were conducted in various species of birds (Barnard *et al.*, 1982) in chicken, (George and Berger, 1996) in pigeon, (Nassar *et al.*, 2001) in guinea fowl, (Meyers and Stakebake, 2005) in albatrosses, (Jennifer *et al.*, 2005) in sparrow, (Biewener, 2011) in pigeon. But there is scanty information in literature on the comparative morphological and histochemical studies of major flight muscle in domestic fowl, guinea fowl and pigeon. Therefore, this work is conducted with aim of comparing gross morphology, gross

morphometry, histology and histochemical studies of the major flight muscles of these birds. These studies will provide a framework for future studies that seek to assess how flight muscles are used to achieve flight across different conditions, and in birds with different wing designs and flight styles.

## Materials and Methods

Fifteen healthy adult birds (five domestic fowls, five guinea fowls and five pigeons) were purchased from a poultry market in Sokoto metropolis. Sokoto metropolis is located on latitudes 10° N and 14° 50 N and longitude 7° E, east of the equator, in the extreme northwest of Nigeria (Mamman, 2000). The birds were caged in well ventilated cages and transported to the Department of Veterinary Anatomy Laboratory, Faculty of Veterinary Medicine, Usmanu Danfodiyo University, Sokoto. Live weights of the birds in grams were all measured using a weighing balance (Sartorius CPA 10001 USA). The birds were sacrificed by severing their jugular veins after which they were de-feathered. The birds were then placed on dorsal recumbency. A sharp pair of scissors was used to cut through the skin around the keel in order to expose pectoralis and supracoracoideus muscles (Major flight muscles). Scalpel blade was further used to detach the muscles from their points of origin and insertion (body of the sternum and keel bone). Gross features of these muscles were carefully examined and recorded. The length, width and weight of these muscles were measured using ruler, measuring tape and weighing balance respectively. The lengths of the muscles were measured from the anterior to the posterior borders of the pectoralis and supracoracoideus. The widths of the muscles were measured as a distance between the

lateral and medial borders at the mid-portion of the muscles. The photographs of these muscles were also taken using a digital camera (Samsung ES95, 16.2 megapixels). Small portions of the muscle tissues were obtained from pectoralis and supracoracoideus and fixed in Bouins solution, followed by preservation in 70% ethyl alcohol. They were dehydrated in ascending concentration of graded alcohol, cleared in xylene and embedded in paraffin wax. Serial section at 5µm were cut and stained with Haematoxylin and Eosin (H&E) and Periodic Acid Schiff (PAS) (Hena *et al.*, 2012).

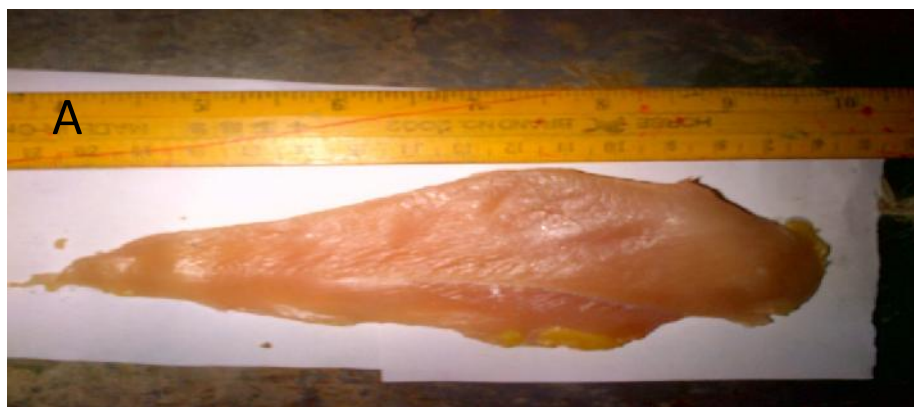Descriptive statistical analytical tool were used to presented data generated from these studies.

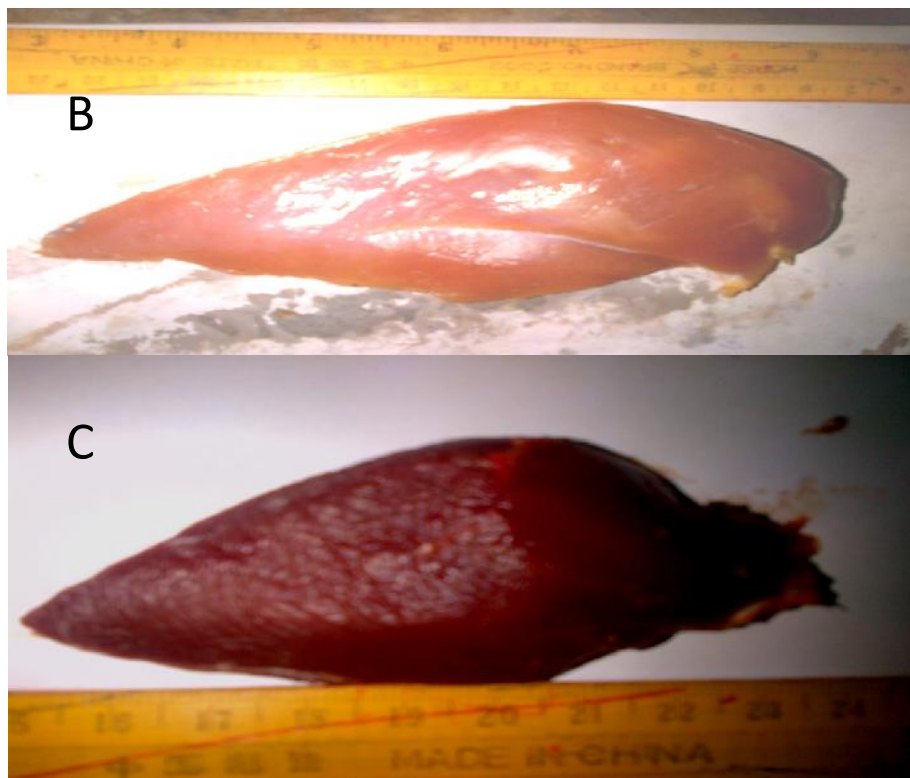
## Results

### Gross Anatomy

#### Pectoralis

In both domestic fowl and guinea fowl, the pectoralis was observed to be pale in color, elongated and complex muscle while in pigeon, it was observed to be red in color, broad and also a complex muscle (Fig. 1). In all the three studied birds, the pectoralis covers the entire ventral surface of the chest region. It arises from the lateral and caudal surfaces of the sternal body, from the lateral surface of the furcula and from adjacent membranes. Pectoralis mainly inserts onto the ventral surface of the pectoral crest of the humerus by an internal aponeurosis. In the domestic fowl, it was divided into distinct sternobrachialis (SB) and thoracobrachialis (TB) portions by an internal sheet of connective tissue.





**Fig. 1:** Showing the pectoralis muscle of domestic fowl (A), guinea fowl (B) and pigeon (C).

**Supracoracoideus**

The colour of supracoracoideus muscle was observed to be white in domestic fowl, red in pigeon and intermediate of the two colours in guinea fowl. It was

also observed to be fusiform-shaped muscle (Fig. 2) and lying deep to the pectoralis on the ventral surface of the body. It arises from the sternal body and keel, it inserts onto the dorsal tubercle of the humerus by mean of its tendon.



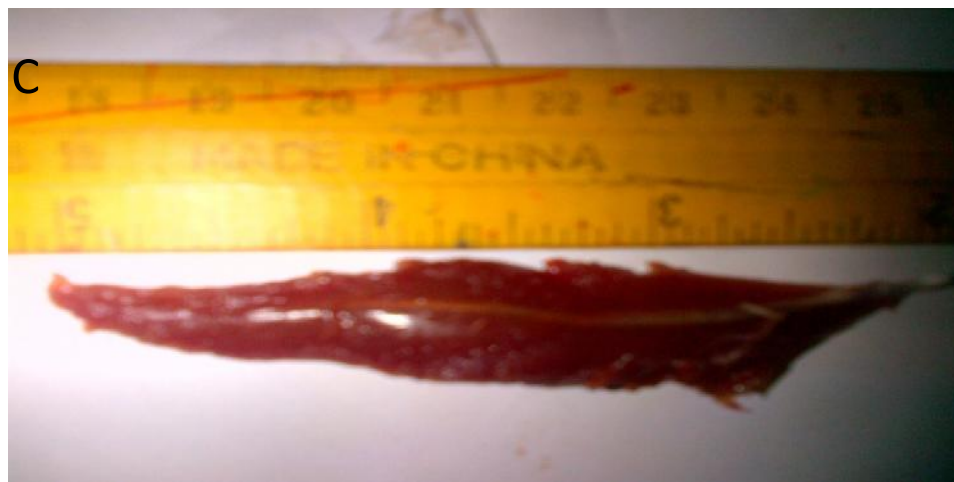


Fig. 4.2: Showing the supracoracoideus muscle of domestic fowl (A), guinea fowl (B) and pigeon (C).

**Morphometry**

**Pectoralis**

The mean ± SEM of weight, length and width of the pectoralis muscle in domestic fowl were 40.12 ± 3.25

g, 15.25 ± 0.32 cm and 6.32 ± 0.11cm respectively. In the guinea fowl, they were 83.37 ± 4.73g, 16.45 ± 0.16 cm and 8.67 ± 0.11 cm respectively while in the pigeon they were 23.25 ±1.30 g, 9.5 ± 0.025 cm and 5.55 ± 0.02 cm respectively as shown in Table 1.

**Table 1: Mean body weight (g), Length (cm), Width (cm) and Weight (g) of the Left and Right Pectoralis muscle in Domestic Fowl, Guinea Fowl and Pigeon.**

SPP	PECTORALIS MUSCLE						
	LEFT			RIGHT			
	BW (g)	L(cm)	WTH (cm)	WT(g)	L(cm)	WTH(cm)	WT(g)
Pigeon	256 ± 2.1	9.5 ± 0.025	5.55 ± 0.02	23.25 ± 1.30	9.5 ± 0	5.52 ± 0.02	23.22 ± 1.31
G. Fowl	1300±40.82	16.45 ± 0.16	8.67 ± 0.11	83.37 ± 4.73	16.47 ± 0.17	8.67 ± 0.15	83.4 ± 4.75
D. Fowl	1325±47.87	15.25 ± 0.32	6.32 ± 0.11	40.12 ± 3.25	15.15 ± 0.25	6.3 ± 0.10	40.1 ± 3.30

The values are expressed as Mean ± SEM.: BW= Body Weight, L= Length, WTH= Width, WT= Weight

**Supracoracoideus**

The mean ± SEM of weight, length and width of the supracoracoideus muscle in domestic fowl were 16.82 ± 2.15 g, 13.25 ± 0.59 cm and 4.12 ±0.37 cm

respectively. In the guinea fowl they were 25.02 ± 1.19 g, 14.05 ±0.05 cm and 4.52 ±0.04 cm while in the pigeon they were 4.45 ± 0.02 g, 8.25 ± 0.02 cm and 2.57 ± 0.02 cm respectively (Table 2).

**Table 2: Mean body weight (g), Length (cm), Width (cm) and Weight (g) of the Left and Right Supracoracoideus muscle in Domestic Fowl, Guinea Fowl and Pigeon.**

	SUPRACORACOIDEUS MUSCLE						
	LEFT			RIGHT			
	BW (g)	L(cm)	WTH (cm)	WT(g)	L(cm)	WTH(cm)	WT(g)
Pigeon	256 ± 2.1	8.25 ± 0.02	2.57 ± 0.02	4.45 ± 0.02	8.22 ± 0.02	2.57 ± 0.2	4.47 ± 0.02
G. Fowl	1300 ± 40.82	14.05 ± 0.05	4.52 ± 0.04	25.02 ± 1.19	14.1 ± 0.05	4.5 ± 0.04	25.05 ± 1.18
D. Fowl	1325 ± 47.87	13.25 ± 0.59	4.12 ± 0.37	16.82 ± 2.15	13.25±0.59	4.1 ± 0.35	16.77 ± 2.09

The values are expressed as Mean ± SEM. BW= Body Weight, L= Length, WTH= Width, WT= Weight

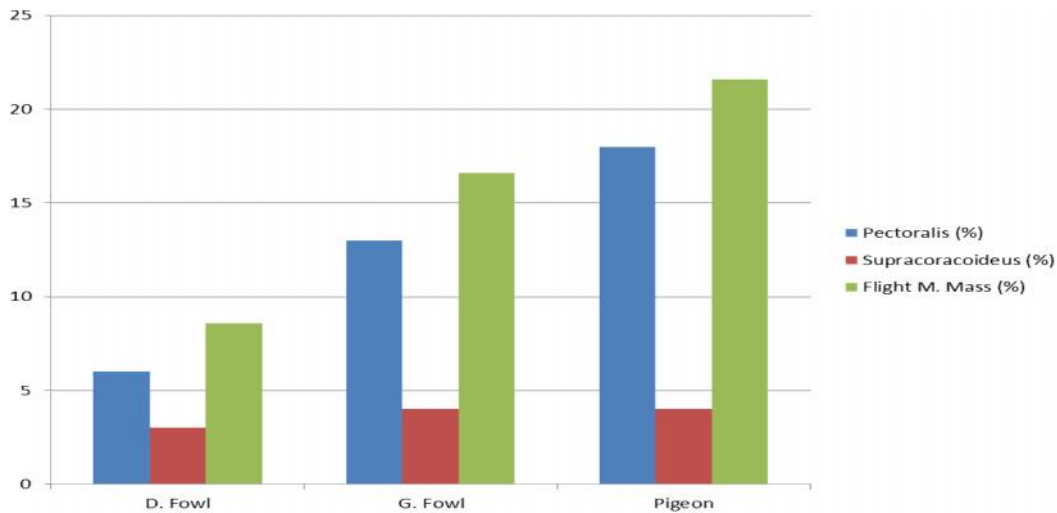


The relative indexes of the pectoralis muscle were 6% 13% and 18% in domestic fowl, guinea fowl and pigeon respectively. While the total flight muscle mass were 70%, 77% and 84% in domestic fowl, guinea fowl and pigeon respectively (Table 3).

The relative indexes of the supracoracoideus muscle were 3%, 4% and 4% in domestic fowl, guinea fowl and pigeon respectively. While the total flight muscle mass were 30%, 23% and 16% in domestic fowl, guinea fowl and pigeon respectively (Table 3).

**Table 4.3: The Relative Indexes of Pectoralis, Supracoracoideus and total Flight Muscle mass in Domestic Fowl, Guinea Fowl and Pigeon.**

Muscle	Domestic Fowl	Guinea Fowl	Pigeon
Pectoralis (%)	6	13	18
Supracoracoideus (%)	3	4	4
Flight muscle mass (%)	8.6	16.6	21.6



**Fig. 3: Relative Index of Pectoralis, Supracoracoideus and Total Flight Muscle Mass in Domestic Fowl, Guinea Fowl and Pigeon.**

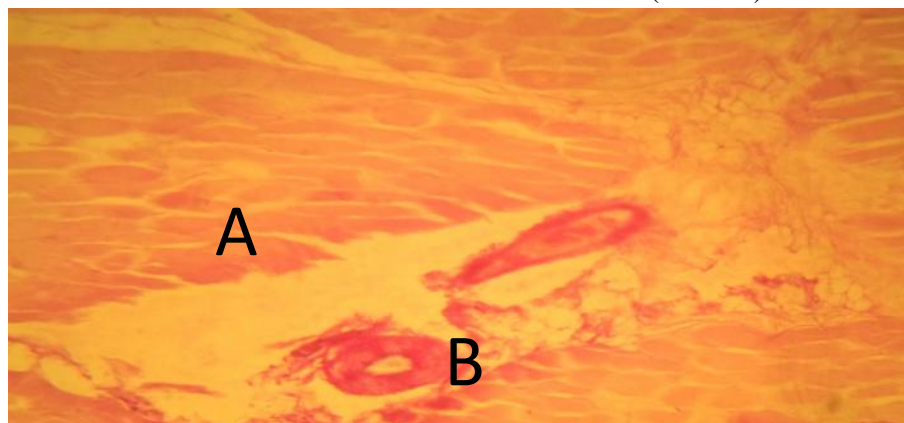
**Histology and Histochemistry**

**Pectoralis**

In domestic fowl, the pectoralis was observed to have thick muscle fibers with smaller and few capillaries, the fiber type of this muscle are typically fast twitch types (Plate I)

In guinea fowl, the pectoralis was observed to have thick muscle fibers with smaller and few capillaries, slow twitch fibers are few with abundant of fast twitch types (Plate II)

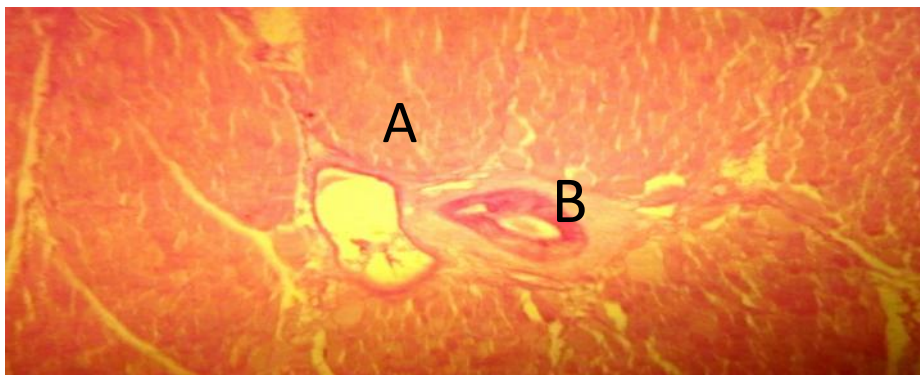
In pigeon, the pectoralis was observed to have very thin muscle fiber bundles with larger and abundant capillaries, slow twitch fibers are abundant with a few fast twitch fibers scattered throughout the muscle bundle (Plate III).



**Plate I:** Photomicrograph of a transverse section of pectoralis muscle of domestic fowl showing the fast twitch thick muscle fibers (A), with smaller capillaries (B). (PAS x40)



**Plate II:** Photomicrograph of a transverse section of pectoralis muscle of guinea fowl showing the fast twitch thick muscle fibers (A), with smaller capillaries (B) (PAS x40)

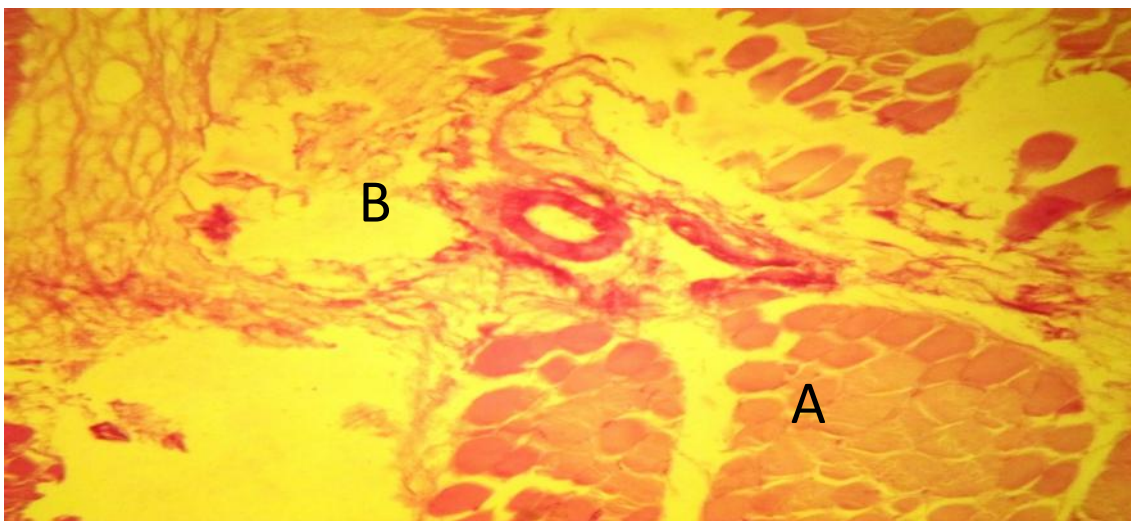


**Plate III:** Photomicrograph of a transverse section of pectoralis muscle of pigeon showing the slow twitch thin muscle fibers (A), with larger capillaries (B) (PAS x40).

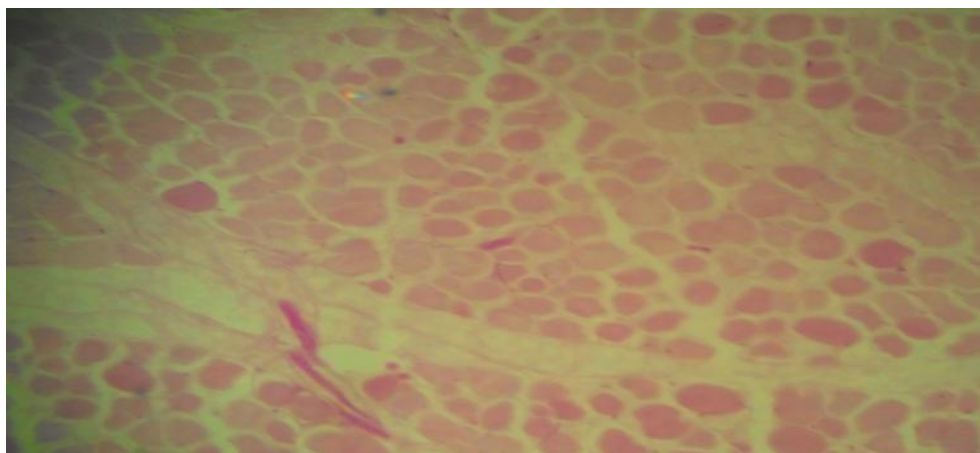
### Supracoracoideus

In all the birds examined (domestic fowl, guinea fowl and pigeon), the supracoracoideus muscle was observed to have the same fiber types (Fast twitch fibers in both domestic fowl and guinea fowl, Slow

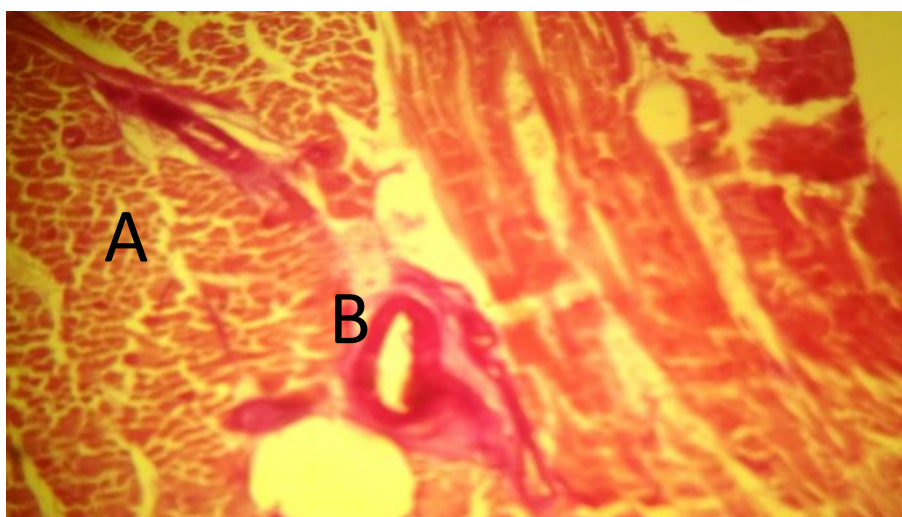
twitch fibers in pigeon as shown on plate I, II and III) and the size of capillaries to their respective pectoralis muscle, but the only observable difference was that the muscle fibers of supracoracoideus was much thicker and less concentrated than the muscle fibers of pectoralis muscle (Plates IV, V and VI).



**Plate IV:** Photomicrograph of a transverse section of supracoracoideus muscle domestic fowl showing densely populated fast twitch thick muscle fibers (A), with smaller capillaries (B) (PAS x40).



**Plate V:** photomicrograph of a transverse section of supracoracoideus muscle of guinea fowl showing densely populated fast twitch thick muscle fibers (A), with smaller capillaries (B) (PAS x40).



**Plate VI:** Photomicrograph of a transverse section of supracoracoideus muscle of Pigeon showing densely populated slow twitch thick muscle fibers (A), with larger capillaries (B) (PAS x40).

## Discussion

### Gross Anatomy

The origin of the pectoralis muscle was generally observed to be similar in all three studied birds. This finding is in line with the finding of Biewener, (2009) in pigeon, who reported that the main portion of pectoralis (sternobrachialis) originates from an enlarged sternal keel with more anterior fibers arising from furcula, a much smaller portion (thoracobrachialis) originates dorsally from the ribs. The present findings were also similar to the report of Geoge, (1959) in pigeon, that pectoralis originates

from an enlarged sternal keel with more anterior fibers arising from furcula, a much smaller portion originates dorsally from the ribs.

The insertion of pectoralis muscle was also observed to be generally similar in all the three studied birds. This finding is in line with the finding of Wada *et al.* (1999) in pigeons and chickens, who reported that pectoralis muscle inserts on the ventral aspect of the humerus. This finding is also similar to the finding of Dial, (1992) in pigeon, who reported that pectoralis also inserts along the ventral proximal shaft of the humerus.



In the present study, the origin and insertion of the supracoracoideus muscle was generally similar across the different species studied. This is similar to the finding of Wada *et al.* (1999) in pigeons and chickens, who reported that the supracoracoideus muscle originates from sternal body and keel, and inserts onto the broad tubercle at the dorsal part of the humerus.

The shape and coloration of pectoralis and supracoracoideus in this study were in agreement with the report of Kiessling (1977) in chicken and pigeon, who reported that the flight muscles of pigeon are redish in color while those of domestic fowl are white in color.

### Morphometry

The mean weight, mean length and mean width for both the pectoralis and supracoracoideus muscles were observed to be higher in guinea fowl, followed by domestic fowl and then pigeon. While the relative indexes of pectoralis muscle were 6%, 13% and 18% in domestic fowl, guinea fowl and pigeon respectively. This is contrary to the findings of Sokoloff *et al.* (1998) in pigeon, who reported that pectoralis is a large muscle of approximately 8-11% body mass. The differences might be due to the differences in the breeds of pigeon used in the study.

George and Berger, (1996) reported as found in this study that, the size of the breast muscles in a bird is related to its flying ability. In the birds that are powerful fliers, over 20% of the birds' weight is breast muscle. In birds that do not fly, less than 10% of the birds' weight comes from the breast muscles. In the present study, 21.6% of the pigeon weight is breast muscle, indicating that the pigeon is a powerful flier, while 8.6% of the domestic fowl weight is a breast muscle, indicating that the domestic fowl is not a powerful flier.

### Histology

The muscle architecture and the physiological properties of muscle fibers are important in the evaluation of muscle capacity. However, more than any other factor, muscle architecture predicts muscle function (Ward *et al.*, 2009).

Variation in fiber type distribution are reflective of the diverse function of avian muscles across species (Wada *et al.*, 1999), the data from the present study support the observation that pigeon may have prone to having flight muscles composed of homogeneous slow

twitch fibers. These fibers are primarily responsible for movement requiring a low degree of force over a prolong period of time in order to support the demand for an excellent sustained flight. On the other hand non-flying birds such as domestic fowl and guinea fowl have a high proportion of fast twitch fibers with few slow twitch fibers in their muscles. These fibers provide muscle movement that supports a large amount of force over a short period of time.

The present findings are similar to the report of Wada *et al.* (1999) in pigeons and chickens, in which the pigeon flight muscle was reported to compose of slow twitch fibers and chicken was reported to compose of fast twitch fibers with few slow twitch fibers scattered throughout. The present findings are however contrary to the findings of Kenneth *et al.*, (2009) in small birds, who reported that three general types of twitch fibers have been recognized as components of avian musculature; slow oxidative fibers, fast glycolytic fibers and fast oxidative glycolytic fibers. This difference may be due to species and breeds variations.

### Conclusion

Since 21.6% of the pigeon weight was breast muscle, it indicated that the pigeon is a powerful flier. Also, with 8.6% of the domestic fowl weight was the breast muscle; it indicated that the domestic fowl is not a powerful flier. Furthermore, this work probably was the first comparative study on the flight muscles of domestic fowl, guinea fowl and pigeon, thus it has established a baseline data for the pectoralis and supracoracoideus muscles in domestic fowl, guinea fowl and pigeon. It is expected that the result will guide further researches on the determination of flying ability in different species of birds.

### Recommendation

It's recommended that the ultrastructural studies of the comparative flight muscles present in the breast muscles of pigeon, domestic fowl and guinea fowl is further studies for more anatomical basis for differentiation.

### Acknowledgments

This work was supported and funded by the Department of Veterinary Anatomy Research Team, Faculty of Veterinary Medicine, Usmanu Danfodiyo University, Sokoto, Nigeria.



## Conflict of interest

The Authors declare that there is no conflict of interests regarding the findings and publication of this work

## References

- Anon.1976. How to improve performance of local chicken, Extention Guide 79 (9). *Ahmadu Bello University Press, Zaria*. 1-7.
- Barnard, E. A., Lyles, J. M., Pizzey, J. A. 1982 . Fibre types in chicken skeletal muscles and their changes in muscular dystrophy. 333-354.
- Baumel, J. J., King, A. S., Breazile, J. E., Evans, H. E., Vanden, Bere, J. C. 1993. Handbook of avian anatomy: 2nd ed. *Cambridge, M.A: Nuttall Ornithol Club*.
- Biewener, A. A. 2011) Muscle Function in avian flight: achieving power and control. *Phil. Trans. R. Soc. B* **366**, 1496-1506
- Biewener, A. A. 2009. The role of intrinsic muscle mechanism in the neuromuscular control of stable running in pigeon. *J. Physio.*, **587**: 2693-2707.
- Bottinelli, R., Reggiani, C. 2000. Human skeletal muscle fibers: molecular and functional diversity. *Prog. Biophys.* 195-262
- Dial, K. P. 1992. Activity patterns of the wing muscles of the pigeon (*Columba livia*) during different modes of flight. *J. Exp. Bio.*, **262**, 357-373.
- F. A. O. 1988. Production Year Book, Volume 39.
- George, J. C. 1959. Studies of the structure and physiology of the flight muscles of birds. Observations on the fiber architecture of the pectoralis major muscles of the pigeon. *Biol. Bull.* **116**: 239-247.
- George, J. C. and Berger, A. J. 1966. Avian Myology. *Academic Press Inc., New York*.
- Gill, F. B. 1995. Ornithology. W. H. Freeman, New York.
- Gordon, A. C. 2007. Breast muscle and fuel for flight. *ga chalmes@telusplanet.net*.
- Grzimek, B. 1992. Grzimek's Animal Life Encyclopedia Vol. 8. Van Nostand Reinhold Company, New York. 43
- Hedenstrom, A. 2008. Adaptation to migration in birds: behavioural strategies, morphology and scaling effects. *Phil. Trans. R. Soc. B* **363**, 287-299.
- Hena, S. A., Sonfada, M. L., Danmaigoro, A. and Bello, A. 2012. Some comparative gross and morphological studies on the gastrointestinal tract in pigeon (*Columba livia*) and Japanese quail (*Coturnix japonica*). *Sci. J. Vet. Adv.*, **1**(2) 57-64.
- Jennifer, M., Karen, L., Sweazea, Eldon, J. B. 2005. Skeletal muscle fiber composition of the English Sparrow (*Passer domesticus*). *Comp. Biochem. Physio.*, **B 143**,126-131.
- Jerry, F. A., Saunders, J. T., Manton, S. M. 2012. A manual of practical vertebrate morphology. *Oxford University Press London*. 52-58.
- John, J. V. 2006. Avian flight: *Oxford university press*. 261.
- Katie, T., Drabble, and Alistear. 1986. The complete textbook of raising livestock and poultry, A small holders guide. *Martin Dunitz Limited, London*. 9-10.
- Keneth, D. 2003. Origin of Bird Flight. *University of Montana Press*.
- Kenneth, C., Welch, J., Douglas, L., Altshuler. 2009. Fiber type homogeneity of the flight musculature in small birds. *Comp. Biochem. Physio.*, **B 152**, 324-331.
- Kiessling, K. H. 1977. Muscle structure and function in the goose, quail, pheasant, guinea hen and chicken. *Comp. Biochem. Physio.* **B 57**, 287-292.
- Komolafe, M. F., Adegbola, A. A., Are, L. A. and Ashaya, I. T. 1979. Agricultural Science for West Africa School. *College University Press Limited, Ibadan*, 23-37.
- Lieber, R. L., Ward S. R. 2011. Skeletal muscle design to meet functional demands. *Phil. Trans. R. Soc. B.* **366**, 1466-1476.
- Mamman, A.B., Oyebanjo, J.O. and Peters, S.W. 2000. Nigeria: A people united, A future assured. (Survey of States), Vol 2. Gabumo Publishing Co. Ltd, London. Pp:32-35.
- Mckitrick, M. C. 1991. Forelimb myology of loons (Gariiformes), with comments on the relationship of loons and tubenoses (Procellariiformes). *Zool. J. Linn Soc.* **102**: 115-152.
- Meyers, R. A., Stakebake, E. F. 2005. Immunohistochemistry of flight muscles and the "shoulder lock" in albatrosses. *J. Morpho.*, **263**,12-29.
- Michael, C., Applyby, Barry, O. Hughes and Anold, E. 1992. Poultry Production Systems, Behavior, Management and Welfare. *Redwood Press, Melksham*. 4-15.
- Ojo, S. A.1990. Guide to the Study and Dissection of Domestic Fowl.*ABU Press Zaria*,35-37.
- Oluyemi, J. F and Robert, F. A. 2007. Poultry production in warm wet climates, Second Edition. *Golden Wallet Press Ibadan*. 27.

- Perrins, C. M., Cousgue, G. and Waine, J. 2003. The new encyclopedia of birds. *Oxford University Press, Oxford*.
- Peter, N. Nassar, Andrew, C. J., and David, R. C. 2001. Entraining the natural frequencies of running and breathing in Guinea fowl (*Numida maleagris*). *The J. Exp. Bio.*, **204**, 1641-1651.
- Pette, D., Staron R. S.1990. Cellular and molecular diversities of mammalian skeletal muscle fibers. *Rev. Physiol., Biochem. Pharmacol.*, 116.
- Raikow, R. 1985. Locomotor system In form and function in birds. *London, UK: Academic press*.
- Sokoloff, A. J., Ryan, J. M., Valerie, E., Wilson, D. S., Goslow, G. E. 1998. Neuromuscular organisation of avian flight muscle: morphology and contractile properties of motor units in the pectoralis (pars thoracicus) of pigeon (*Columba livia*). *J. Morpho.*, **236**, 179-208.
- Wada, N., Miyata, H., Tomita, R., Ozawa, S., Tokuriki, M.1999. Histological analysis of fiber composition of skeletal muscles in pigeons and chickens. *Arch. Ital. Biol.* **137**, 75-82.
- Ward, S. R., Eng, C. M., Smallwood, L. H., Lieber, R. L. 2009. Are current measurements of muscle architecture accurate?. *Clin. Orthop. Relat. Res.* **467**: 1074-1082.

<b>Access this Article in Online</b>	
	<b>Website:</b> <a href="http://www.darshanpublishers.com">www.darshanpublishers.com</a>
	<b>Subject:</b> <b>Veterinary Sciences</b>
<b>Quick Response Code</b>	

**How to cite this article:**

Danmaigoro A., Shehu, S.A., Habibu, H., Hena, S. A., Mahmud, M. A., Bello, A. (2016). Comparative Morphological and Histochemical Studies on Major Flight Muscles of Domestic Fowl (*Gallus gallus domesticus*), Guinea Fowl (*Numida maleagris*) and Pigeon (*Culumba livia domesticus*). *Int. J. Curr. Res. Biol. Med.* 1(3): 29-38.