

---

# INTERNATIONAL JOURNAL OF CURRENT RESEARCH IN BIOLOGY AND MEDICINE

ISSN: 2455-944X

[www.darshanpublishers.com](http://www.darshanpublishers.com)

DOI:10.22192/ijcrbm

Volume 1, Issue 8 - 2016

**Original Research Article**DOI: <http://dx.doi.org/10.22192/ijcrbm.2016.01.08.002>

## Radiographic Evaluation of Alveolar Ridge Height of Maxilla and Mandible Bone in Edentulous Men

**Nasim Shams<sup>1</sup>, Hossein Ebrahimi<sup>2\*</sup>**

<sup>1</sup>Assistant Professor, Department of Oral and Maxillofacial Radiology, Faculty of Dentistry, Ahvaz Jundishapur University of Medical Sciences, Ahvaz, Iran.

<sup>2</sup> Student Research Committee, Faculty of Dentistry, Ahvaz Jundishapur University of Medical Sciences, Ahvaz, Iran.

**Corresponding author: Hossein Ebrahimi**, Student Research Committee, Ahvaz Jundishapur University of Medical Sciences, Ahvaz, Iran.

**E-mail:** Ebrahimi.Hossein@rocketmail.com

---

### Abstract

**Objectives:** Edentulous is the most common organ defects in the communities & shows the prevalence of this disability community's health. The World Health organization (WHO) recorded index periodically at intervals of a certain age as a determinant of oral health status has been recommended. The aim of this study was to radiographic evaluation of alveolar ridge height of maxillary and mandibular bone in edentulous men.

**Material and Methods:** In this study, the team studied include of 96 patients referred to the radiology department of Ahvaz University of Medical Sciences during the July 2015 date was October 2016. After obtaining informed consent from individuals and fill out the form information, the panoramic radiograph was obtained. The results of this study using SPSS version 22, using descriptive statistics and T-test were analyzed statistically. P 0.05 was considered significant extent.

**Results:** In the present study showed in both maxillary & mandibular alveolar bone height (molars and premolars and midline in the area of the left and right).

**Conclusions:** So after tooth extraction or tooth loss, before resorption to begins in different areas, we should think about appropriate treatment plan to prevent destruction of the edentulous.

**Keywords:** Panoramic radiography, alveolar ridge, Residual ridge, edentulous

---

### Introduction

Local and systemic factors such as dental caries and periodontal disease can affect the dental system. Edentulous is the end result of dental caries and periodontal disease (1). Edentulous is the most common organ defects in the communities & shows the prevalence of this disability community's health. The World Health organization (WHO) recorded index periodically at intervals of a certain age as a determinant of oral health status has been recommended (2). In some

of the mandible after loss of teeth, shows severe resorption (3). After extracting teeth, alveolar ridge resorption occurs, which results in the loss of 40% and 60% height of the ridge within six months (4). Alveolar bone resorption after tooth loss leads to prosthesis mismatch on alveolar tissue Which ultimately not will leads to patient discomfort as well as beauty and correct operation (3, 5). Sometimes it can also lead to defects in alveolar crest bone after tooth extraction is a three-

dimensional analysis(6). low Support of alveolar bone, probably the most common and challenging problem and a non-negligible Case(7). Periodontal changes related changes as well as periodontal disease is related to intrusion and extrusion. In orthodontic tooth movement in the horizontal and vertical layers is a high osteogenic potential (1). Other cases that cause bone loss are osteoporosis that a progressive systemic disease is the result of an imbalance between bone formation occurs and resorption process (8,7,9). Alveolar bone formation and resorption of bone height is influenced by two variable Process(10). During alveolar bone loss, the residual ridge is a decrease in size and change in shape(11). The remaining bone resorption patterns are influenced by a variety of local and systemic factors such as the patient's age, traumatic damage, different pathological conditions, mineral metabolism disorders, osteoporosis, Osteoporosis, hormonal imbalance(7). characterize the amount of alveolar bone loss can use in such as complete dentures and implants for tooth replacement therapy (12). Predictable medical treatment with dental implants has been proven as a way to replace missing teeth with implants as fixed and removable prosthesis(13). Measure the height of the alveolar bone could prejudice the dentist in the areas of implant insertion in edentulous patients with implant supported denture is that candidates get help(14). In studies that have been done in the past, the relationship between age, sex, duration, edentulous alveolar bone loss and other factors is performed (14,15,16,17,18,19,20,21,22). So with regard to importance of bone loss and reduction in height of the alveolar ridge and periodontal treatment Orthodontic and Implant, in this study radiographic alveolar ridge height in the edentulous maxilla and mandible in relation to men age will be discussed.

## Materials and Methods

In this study the study group, 96 patients referred to the Radiology, Faculty of Dentistry, Ahvaz Jundishapur University of Medical Sciences, Ahvaz, during October 2015 to July 2016. Inclusion criteria include: Refer to the School of Dentistry, Ahvaz Jundishapur University of Medical Sciences see the October 2015 to July 2016, a willingness to cooperate in this research, and Exclusion criteria include: Not having any of the inclusion criteria and systemic diseases affecting bone remodeling (hyperparathyroidism, hyperadrenalism and hypoadrenalism), jaw lesions, prior use of drugs affecting bone remodeling, having periodontal disease.

affecting the bone that may include dehiscence, fenestration, age-

The required information through a questionnaire survey among patients referred to the radiology clinic, Ahvaz University of Medical Sciences collection and 96 patients who qualified and consent to enter the study, were included. In order to collect data such as medical and dental history and screening questionnaire contains 19 questions regarding medical history and 3 questions concerning Dental history were given to the patients. Then, after completing and collecting the questionnaires, the question of the systemic health, age, number of teeth, was investigated

for edentulous. The next time the panoramic radiography patients who have symptoms of diseases affecting bone or jaw lesions were seen, were excluded from this study. After full knowledge, consent and obtain the necessary qualifications to participate in the study, patients in both groups: with teeth (48 cases) and toothless (48 cases). Groupings based on the remaining teeth was conducted in the following method(18). The control group include patients were at least 20 teeth in both jaws, including teeth anterior and posterior teeth in each quadrant are at least 3. The cases group (edentulous) were toothless patients with complete or partial, and up to 10 teeth in both jaws, including 4 anterior teeth and 6 posterior teeth (19). Imaging done with panoramic machine (D Cranex's model that manufacturing by Sordex company in Finland) that was in radiology department at the University of Ahvaz. The exposure conditions and adjust depending on the size of the jaw and person body were chosen.

In images obtained if evidence of bone disease or systemic disease were excluded. To measure of device's magnification was used three types dry mandible. And three metal balls of a characterized size in the anterior area and a four number in the posterior region of the mandible and magnifying devices were measured in this way. Then measurements in both groups of patients was 10 area of the panoramic image (figure 1). The reference lines and measurement points were marked manually on the panoramic radiographs with a 0.5-mm lead pencil on a standard light box. Alveolar ridge bone size in the mandible based on reference lines from the tangent to the lower border of mandible(D1 and D2)

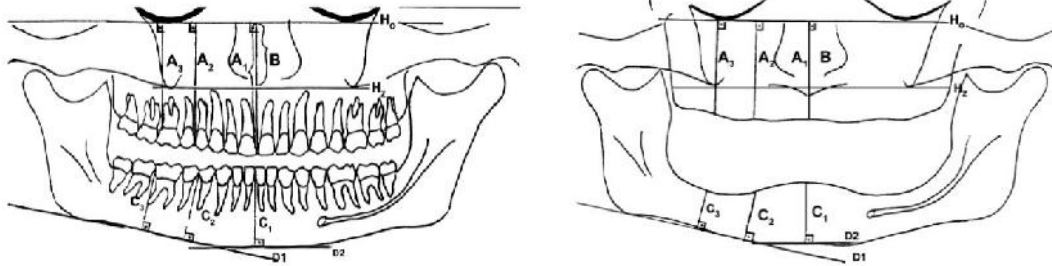
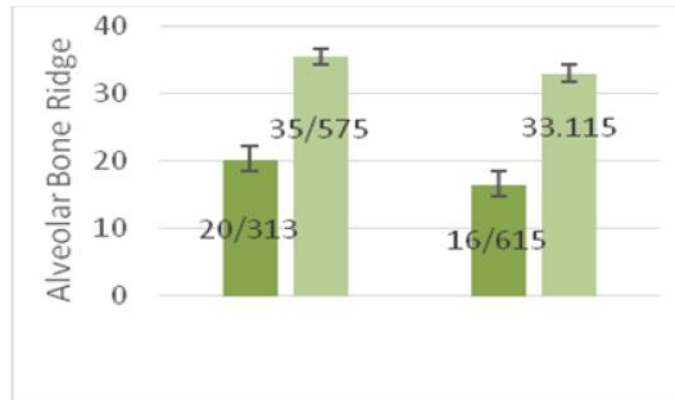


Figure 1- measurement points incase & control group

**Results**

In studies it was shown in this research the height of the alveolar ridge in the maxillary and mandibular midline in control group individuals 20.31mm and 35.57mm And in case group are 16.61mm and

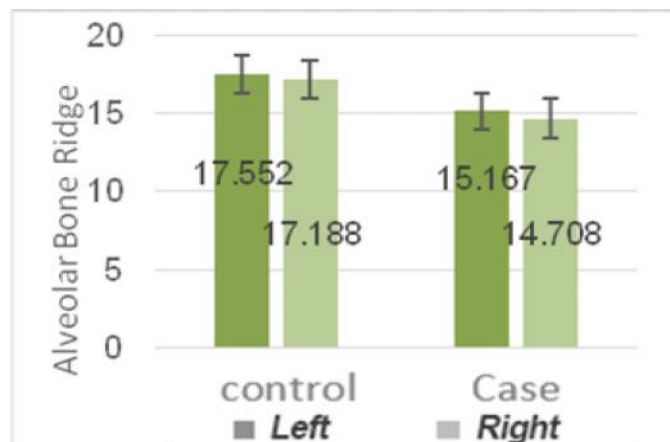
33.11mm (Graphs1).It was also found significant differences between control group and case group in height of the alveolar ridge in the maxillary (P: 0.0001) and mandibular (P: 0.007) midline.



Graphs 1- Evaluation of maxillary and mandibular alveolar ridge height in the midline Area

In studies it was shown in this research the height of the alveolar ridge in the maxillary molar on the left and right in control group individuals 17.55mm and 17.18mm, in case group are 15.16mm and 14.70mm.

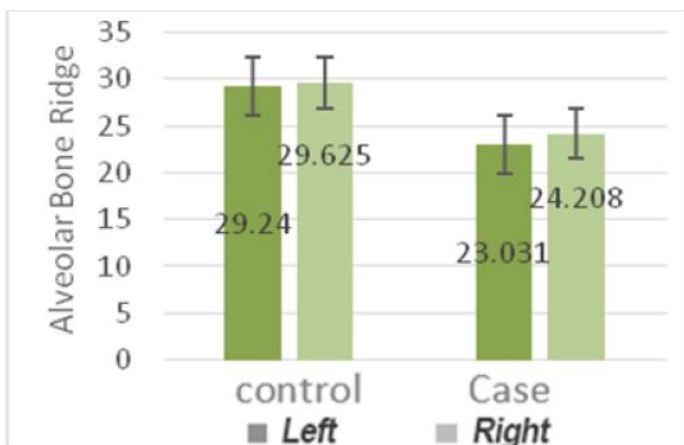
(Graphs2).It was also found significant differences between control group and case group alveolar ridge height in the maxillary molar on the left side (P: 0.0001) and right side (P: 0.001).



Graph 2- Evaluation of the maxillary alveolar ridge height on the left and right molar area

In studies conducted in this research it was found that the height of the alveolar ridge in mandibular molar on the left and right in control group individuals 29.24mm and 29.62 mm and in case group are

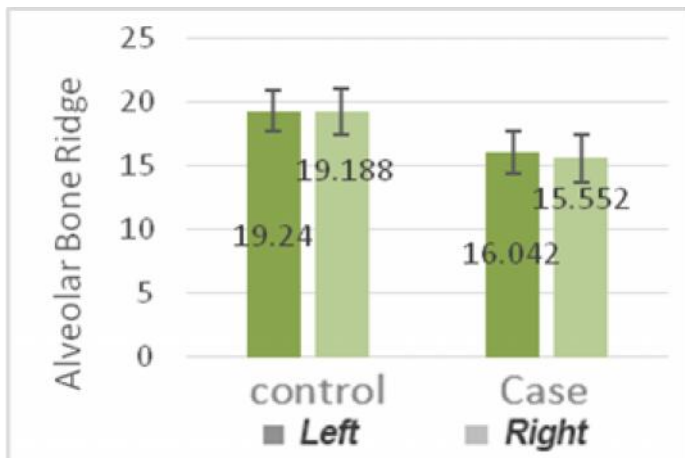
23.03mm and 24.20mm(Graph 3).It was also found significant differences between control group and case group alveolar ridge height in the mandibular molar on the left side (P: 0.0001) and right side (P: 0.0001).



**Graph 3-** Assessment of alveolar ridge height of the mandibular molar area on the left and right

In studies conducted in this research it was determined that the height of the alveolar ridge in the maxillary premolar region. The left and right side in control group individuals 19.24mm and 19.18 mm and in case group are 16.04mm and 15.55mm (Graph 4). It was

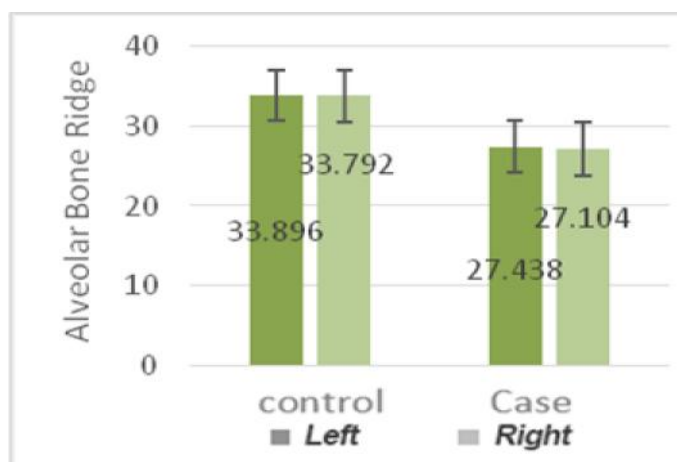
also found significant differences between individuals control group and case group alveolar ridge height in the maxillary premolar region on the left side (P: 0.0001) and right side (P: 0.0001).



**Graph 4-** Evaluation of the maxillary alveolar ridge height on the left and right premolar

In studies conducted in this research it was found that the height of the alveolar ridge in the mandible in the area Premolar left and right in control group individuals 33.89mm and 33.79mm and in case group 27.43mm and 27.10mm (graph5). it was also

found significant differences between subjects control group and case group in the lower jaw alveolar ridge height in the left premolar region (P: 0.0001) and right (P: 0.0001).



**Graph 5-** Evaluation of mandibular alveolar ridge height on the left and right premolar region

## Discussion

Radiographic imaging tool is helpful Which may be accompanied by physical exam and medical history, led to the diagnosis and treatment planning. Basically, procedures should have the ability to correct diagnosis. The best diagnostic method that similar results replicated and cause and the presence or absence of properly surveyed show (20).

In the present study it was found that the height of the alveolar ridge in the maxillary and mandibular midline 31.20 mm and 57.35 mm in control group individuals and in case group 16.61mm and 11.33 mm and no significant differences between control group and case group at the height of the alveolar ridge in the maxillary (P: 0.0001) and mandibular (P: 0.007) midline. the height of the alveolar ridge in the maxillary molar on the left and right 17.55mm and 17.18mm in control group and in case group 15.16mm and 14.70mm and the difference between the control group and the edentulous ridge height alveolar maxillary molar on the left side (P: 0.0001) and right (P: 0.001) was found. The height of the alveolar ridge in mandibular molar on the left and right in order of 24.29mm and 29.62 mm in control group individuals and in case group 23.03mm and 24.20mm and height were significant differences between control group and case group at the alveolar ridge in mandibular molar on the left side (P: 0.0001) and right (P: 0.0001). maxillary alveolar ridge height on the left and right premolar region 19.24 mm and 19.18 mm in control group individuals and in case group 16.04mm

and 15.55mm are significant differences between control group and case group alveolar ridge height in the maxillary premolar region on the left side (P: 0.0001) and right (P: 0.0001). the height of the alveolar ridge in the mandible in the premolar on the left and right 33.89mm and 33.79mm, respectively, in control group and 27.43mm and 27.10 mm for case group, and no significant differences between control group and case group the height of the alveolar ridge in the mandible in the premolar on the left side (P: 0.0001) and right (P: 0.0001).

In a study by Dutra et al (15) to determine the radiographic mandibular bone remodeling in adults in America in 2003. they were divided into three groups were opposed to it, after like those in this study sex, oral health and age of the patients was recorded. in their study, measurements were performed by two observers, but in this study an observer was used. finally, it was determined that no change of the mandibular angle in relation to gender, age and dental condition is not shown, while the pattern of resorption was antegonial areas in toothless mandible.

Also not shown significant difference for the mandibular angle in relation to age, sex and edentulous, but in this study it was shown that edentulous patients compared to healthy are significant differences in bone loss ,the results of the study showed pushed in all areas identified in the group of teeth is more than the control group.

Results Van der Weijden et al (16) showed that after extraction the alveolar ridge in both height and width have resorption. in line of their study in this study, with the duration of edentulous, alveolar ridge height in midline area was determined that no significant difference between groups in the maxillary midline ridge height (P: 0.019) and mandibular midline (P: 0.0001).were also significant differences between categories of edentulous and ridge height in mandibular left first molar (P: 0.017) and mandibular right molar (P: 0.005) was found. Significant differences between edentulous and ridge height in the groups in the maxillary left premolar (P: 0.019) and mandibular left premolar (P: 0.0001) and mandibular right premolars (P: 0.001).

The results Lopez-Roldan et al (17) showed that although bone loss in the Premaxilla, the mandibular denture supported by implants significantly reduces bone resorption. in the present study it was shown that the height of the alveolar ridge in the maxilla and mandible midline 20.31mm and 35.57mm in control group individuals and in case group 16.61mm and 33.11mm and the difference between all groups in the maxilla (P: 0.0001) and mandible (P: 0.007) there midline. Therefore, in this study it was shown in the resorption is the most in maxillary midline.

In the study of Ural and et al (14) Ortman et al (21) and De Beet et al (22) demonstrated that all vertical distances measured in the edentulous maxilla and mandible was significantly greater in men than women edentulous with it in the present study it was found that only the men were edentulous resorption more is on the maxilla.

As Canger and Celenk study (19) that no significant difference between the height of the alveolar ridge in edentulous patients and the natural dentition was observed in this study, significant differences were observed in different parts of the alveolar ridge height, so that in this study no significant differences between all groups in midline of the maxillary alveolar ridge height (P: 0.0001) and mandibular ridge height (P: 0.007) was found. also no significant difference between the control group and case group in the maxillary alveolar ridge height in the molar area on the left side (P: 0.0001) and right (P: 0.001) was found.

In addition to between the healthy and the toothless alveolar ridge height in the left mandibular molar area (P: 0.0001) and right (P: 0.0001) there are significant differences as well as differences between control group and edentulous alveolar ridge height in

maxillary premolar region on the left side (P: 0.0001) and right (P: 0.0001) was there. no significant difference between the control group and edentulous alveolar ridge height in the lower jaw on the left premolar region (P: 0.0001) and right (P: 0.0001) was observed.

Xie et al (23) no significant differences between control group and in both sexes were toothless. Like their study found that alveolar height of the mandible and maxilla in edentulous patients is lower than in control group. In addition, they found in their study that in edentulous patients with mandibular alveolar reduction in height is more than maxillary but the toothless men in the study were only examined, it was found that resorption is more in the maxilla.

## Conclusion

According to the results of this study showed resorption occur in both maxillary & mandibular alveolar bone height (molars and premolars and midline in the area of the left and right). So after tooth extraction or tooth loss, before resorption to begins in different areas, we should think about appropriate treatment plan to prevent destruction of the edentulous.

## Acknowledgments

This work was financially supported by grant: Gp94047 from vice-chancellor for research Affairs of Ahvaz Jundishapur University of Medical Sciences. This study is issued from thesis of Hossein Ebrahimi.

## References

1. Bonakdarchian M, Ghorbanipour R, Majdzadeh F, Hojati T. Prevalence of edentulis among adults aged 35 years and over and associated factors in Yasooj. Journal of Isfahan Dental School 2011; 7(1): 101-104.
2. Shagayegh SH, Salari AM. A study of the prevalence edentulous cases in Iran during 1998-1999. Beheshti Univ. Dent. J. 2003; 21(1): 61-65.
3. Kingsmill V. Post-extraction remodeling of the adult mandible. Crit Rev Oral Biol Med 1999; 10(3):348-404.
4. Hoffmann O, Bartee BK, Beaumont C, Kasaj A, Deli G, Zafiroopoulos GG. Alveolar bone preservation in extraction sockets using non-resorbable dPTFE membranes: a retrospective non-randomized study. J Periodontol 2008; 79(8): 1355-1369.

5. Kubo CS, Amaral FR, De Campos EA. Relining of removable dentures: a literature review. *RSBO* 2014; 11(2): 192-198.
6. Stimmelmayer M, Guth JF, Schlee M, Gohring TN, Beuer F. Use of a modified shell technique for three-dimensional bone grafting: Description of a technique. *Australian Dental Journal* 2012; 57(1): 93-97.
7. Knezovic Zlataric D, Celebic A, Lazic B. Resorptive Changes of Maxillary and Mandibular Bone Structures in Removable Denture Wearers. *Acta Stomat Croat* 2002; 36(2): 261-265.
8. Postic, PhD SD, Vujasinovic-Stupar N, Rakocevic Z. Systemic Osteoporosis and Reduction of the Edentulous Alveolar Ridge. *International Journal of BioMedicine* 2013; 3(3): 201-206.
9. Khojastepour L, Dabaghmanesh MH, Irajinasrabadi N, Mogharrabi S. Comparison of the Amount of Alveolar Bone Loss and the Number of Remaining Teeth in Postmenopausal Women with and without Normal Bone Mass. *J Mash Dent Sch* 2013; 36(4): 285-92.
10. Shah Abouei M, Hekmatian E, Adibrad M, Bahador Ghobadi A. Accuracy of vertical bitewing and bisect periapical radiography techniques in anterior mandibular teeth interdental bone resorption using grid sheet. *Journal of Isfahan Dental School* 2009; 5(3): 126-133.
11. Kranjcic J, Stunic MK, Celebic A, Komar D, Mehulic K, Vojvodic D. Denture Relining As an Indicator Of Residual Ridge Resorption. *Med Glas Ljek komore Zenicko-doboj kantona* 2013; 10(1):126-132.
12. Monzavi A, Farhang GHR. A comparison study of stress distribution around dental implants in three mandibular arch types by finite element analysis. *Tehran Uni of Med sci, J of dentistry*. 2001; 13(3-4): 12-19.
13. Hadi A, Saboury A. Recommended loading protocols for dental implants in edentulous and partially edentulous patients with fixed or removable prosthesis. *J Dent Sch*. 2011; 29(2): 111-132.
14. Ural C, Bereket C, Sener , Aktan AM, Akpınar YZ. Bone height measurement of maxillary and mandibular bones in panoramic radiographs of edentulous patients. *J Clin Exp Dent* 2011; 3(1): 5-9.
15. Dutra V, Yang J, Devlin H, Susin C. Mandibular bone remodelling in adults: evaluation of panoramic radiographs. *Dentomaxillofacial Radiology* 2004; 33: 323-328.
16. Van der Weijden F, Dell'Acqua F, Slot DE. Alveolar bone dimensional changes of post-extraction sockets in humans :a systematic review. *J Clin Periodontol* 2009; 36: 1048-1058.
17. Lopez-Roldan A, Santolaya-Abad D, Gregori-Bertomeu I, Gomez-Castill E, Selva-Otaolaurruchi E. Bone resorption processes in patients wearing overdentures: A 6-years retrospective study. *J Clin Exp Dent* 2009; 1(1): e24-30.
18. Jagadeesh MS, A Patil R, T.Kattimani P. Clinical Evaluation of Mandibular Ridge Height In Relation To Aging and Length of Edentulism. *IOSR Journal of Dental and Medical Sciences*2013; 3(4): 44-47.
19. Canger EM, Celenk P. Radiographic evaluation of alveolar ridge heights of dentate and edentulous patients. *Gerodontology* 2012; 29: 17-23.
20. Akkaya N, Kansu O, Kansu H, Cagırankaya LB, Arslan U. Comparing the accuracy of panoramic and intraoral radiography in the diagnosis of proximal caries. *Dentomaxillofac Radiol*. 2006; 35(3): 170-4.
21. Ortman LF, Hausmann E, Dunford RG. Skeletal osteopenia and residual ridge resorption. *J Prosthet Dent*. 1989; 61: 321-5.
22. de Baat C, Kalk W, van't Hof M. Factors connected with alveolar bone resorption among institutionalized elderly people. *Community Dent Oral Epidemiol*. 1993;21: 317-20.
23. XieQ, Wolf J, Ainamo A. Quantitative assessment of vertical heights of maxillary and mandibular bones in panoramic radiographs of elderly dentate and edentulous subjects. *Acta Odontol Scand* 1997; 55: 155-161.

#### Access this Article in Online



**Website:**

[www.darshanpublishers.com](http://www.darshanpublishers.com)

**Subject:**

Dental Sciences

**Quick Response  
Code**

#### How to cite this article:

Nasim Shams, Hossein Ebrahimi (2016). Radiographic Evaluation of Alveolar Ridge Height of Maxilla and Mandible Bone in Edentulous Men. *Int. J. Curr. Res. Biol. Med.* 1(8): 9-15.

DOI: <http://dx.doi.org/10.22192/ijcrbm.2016.01.08.002>