

INTERNATIONAL JOURNAL OF CURRENT RESEARCH IN BIOLOGY AND MEDICINE

ISSN: 2455-944X

www.darshanpublishers.com

DOI:10.22192/ijcrbm

Volume 2, Issue 8 - 2017

Review Article

DOI: <http://dx.doi.org/10.22192/ijcrbm.2017.02.08.003>

Calciphylaxis - A Brief Review

*N.S. Neki, **Swati Prabhakar, ***Alaipreet Kaur, ****Ashish Kumar Ludhar,

* Professor, Dept. of Medicine, Govt. Medical College/ Guru Nanak Dev Hospital, Amritsar, India, 143001

**Medical Intern (Ex), Govt. Medical College, Amritsar, India

***Medical Student, Govt. Medical College, Amritsar, India

****Medical Officer, SHC Pasla, Distt Jalandhar.

Corresponding Author: **Dr. Swati Prabhakar**, Medical Intern(Ex), Govt. Medical College, Amritsar, India, 143001, E- mail:swatiprabhakar@yahoo.com

Introduction

Calcific uremic arteriopathy(CUA) or calciphylaxis is an enigmatic rarity defined by calcific vasculopathy of small and medium-sized vessels in the dermis and subcutaneous tissue that leads to ischemic necrosis of surrounding tissue. [1] Histologically there is calcium deposits in the medial layer of the small to medium vessels of the reticular dermis and subcutaneous fat. Patients with chronic uremia in end stage renal disease patients (ESRD) with hyperparathyroidism are at risk of calciphylaxis[5]. However, it is even seen in the setting of normal renal function termed as non -

uremic calciphylaxis(NUC) which is discussed in this article. In this article calciphylaxis due to uremic cause is referred to as CUA whereas calciphylaxis due to other causes is referred as NUC whereas collectively it is referred to as calciphylaxis

Etiology

The etiology of CUA is multifactorial and its estimated prevalence is reported in up to 4% of patients on dialysis with ESRD. Factors suggestive of promoting CUA are listed in Table 1 [4,6,8].

Table 1

Hyperphosphatemia,
Hypercalcemic states (including secondary hyperparathyroidism),
Milk-alkali syndrome,
Hypervitaminosis D
Elevated calcium-phosphate product.
Other predisposing factors:
Diabetes mellitus
Peritoneal dialysis
Hypoalbuminemia associated with chronic inflammation
Malnutrition
Hypertension
Atherosclerosis

These factors contribute to the chemical microenvironment inducing calciphylaxis. Ionized calcium in the blood may also play a role in the pathogenesis of this process. An increase in blood calcium levels is known to elevate the blood pressure and may have a direct vasoconstrictive effect. [7]. Non-Uremic Calciphylaxis (NUC) as mentioned earlier, is seen in the setting of normal renal function. It's

etiopathology is poorly understood. But according to the recent studies there are some associated factors that may be contributing to the chemical milieu inducing calciphylaxis [4] that are listed in table 2. Frequently reported common risk factors in NUC are excessive body mass index, Caucasian ethnicity, female sex, and diabetes mellitus [9]

Table 2
Primary hyperparathyroidism,
Connective tissue diseases
Alcoholic liver disease
Malignancy
Other factors contributing are:
Diabetes
Chemotherapy induced (cyclophosphamide, Adriamycin, and fluorouracil)
Corticosteroid
Warfarin
Protein C and S deficiency
Crohn disease
POEMS syndrome
Vitamin D deficiency
Weight loss
Chronic kidney disease (not ESKD) , and
Osteomalacia treated with nadroparin calcium.

Pathogenesis

Calcific uremic arteriopathy was first described by Hans Selye in 1962 on animal models. He induced calcification of various organs by exposing the animals to one of the several sensitizing agents referred to as "calcifiers" e.g., dihydrotachysterol, vitamin D, parathyroid hormone, followed by exposure to a "challenger" e.g., metallic salts such as iron and aluminum, egg albumin, trauma. He proposed a theory of "sensitizers" and "challengers" through his experiment. A few years later, a case of calcifying panniculitis with renal failure was reported as calciphylaxis in 1968 and that case was accompanied by the presence of large painful lumps in the fat of thighs and knees, over which the skin rapidly became necrotic. Through his work, Selye laid the foundation for understanding this debilitating disease in humans, describing it as a rare complication of chronic kidney disease (CKD) and secondary hyperparathyroidism involving the dermis and vasculature. [1,4,8,17]

The pathogenesis is initiated with interaction of the uremic factors (discussed above) and decrease of local vascular calcification inhibitory proteins such as Matrix Gla protein (MGP) and the systemic globulin fetuin-A—(a2-Heremans-Schmid glycoprotein) AHSG. They inhibit vascular calcification and deficiencies of these inhibitors may play a role in CUA pathogenesis.

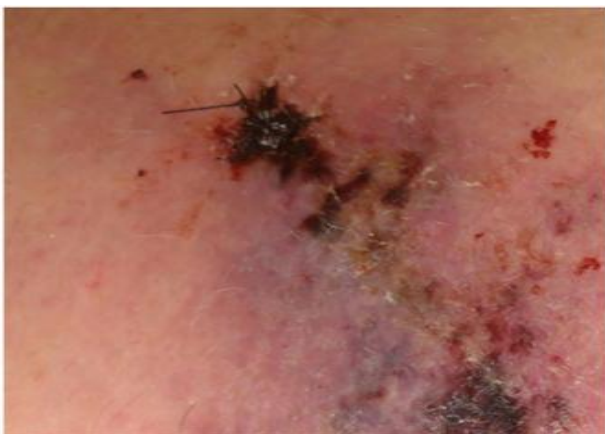Fetuin-A is a serum glycoprotein that binds calcium and phosphate in the circulation, thereby forming "calciprotein particles" that help clear the circulation of excess calcium and phosphate. In animal models, fetuin-A limits organ and soft-tissue calcification and vascular calcium deposition. Vitamin D-mediated tissue calciphylaxis is associated with fetuin-A downregulation.

Low fetuin-A levels also correlate with a chronic inflammatory state and cardiovascular calcification in hemodialysis patients. Compared with healthy individuals, serum fetuin-A levels from hemodialysis patients are lower and have diminished capacity to inhibit ex-vivo calcium and phosphate precipitation.

Matrix Gla protein(MGP) is a mineral-binding extracellular matrix protein that is synthesized by vascular smooth muscle, endothelium, and chondrocytes. MGP inhibits calcification of arteries and cartilage in an animal model. MGP activity depends upon vitamin K-dependent carboxylation. This is relevant because warfarin-induced inhibition of vitamin K-dependent carboxylation of MGP may be a mechanism by which warfarin increases the risk of calciphylaxis especially NUC.[2,4,8]

Derangements of receptor activator of NF B (RANK), RANK ligand, and osteoprotegerin may also be involved in the pathogenesis of calciphylaxis because this system is involved in regulation of extraskeletal mineralization. Some of the factors that predispose to NUC (parathyroid hormone, corticosteroids, and liver disease) are known to increase the expression of RANK ligand and decrease the expression of osteoprotegerin, thus activating NF B or degrading the inhibitory protein of NF B (or a combination of these)[4] In a case of weight loss-related calciphylaxis, increased levels of systemic matrix metalloproteinases were thought to be etiologically important. In several studies use of systemic corticosteroids is found to be associated with high mortality rate in patients with this disease, although its exact pathological role is yet to be studied.[2,4]

The deposition of calcium phosphate in subcutaneous vessels in patients with calciphylaxis is thought to be due to increased expression of osteopontin which is a chemoattractant as evidenced in the skin biopsies of patients with calciphylaxis. Osteopontin is secreted



among other matrix proteins by smooth muscle cells that dedifferentiate into osteoblast like cells. [3]

Clinical Manifestation

The clinical manifestations of calciphylaxis result from reductions in the arteriolar blood flow. Reduced blood flow is caused by calcification, fibrosis, and thrombus formation primarily involving the dermo-hypodermic arterioles.

Medial vessel calcification occurs first. Ongoing vascular endothelial injury causes cutaneous arteriolar narrowing and a hypercoagulable state that causes tissue infarction. [2] The appearance of the lesions depends on the time of presentation. Early ischemic changes may present as violaceous reticulated patches (retiform purpura) resembling livedo reticularis (picture 1 in fig.1). The most characteristic lesions are violaceous, painful, plaque-like subcutaneous nodules that progress to ischemic/necrotic ulcers with eschars once vascular thrombosis is advanced (picture 2 in fig.1). Eschars often become superinfected.

CUA is characterized by excruciating pain [1,4]. In some patients, pain may precede the development of skin lesions. The exact mechanism of pain in CUA is unclear and is thought to be ischemic in origin, but there may be a neuropathic component [2]. Lesions develop in areas with greatest adiposity, including the thighs, abdomen, and buttocks [2,4]. Rarely lesions may affect the upper extremities, and some patients may have digital ischemic lesions.

Ischemic myopathy, presenting as painful proximal muscle weakness, is a less frequent manifestation that can occur without skin necrosis.[2,9]

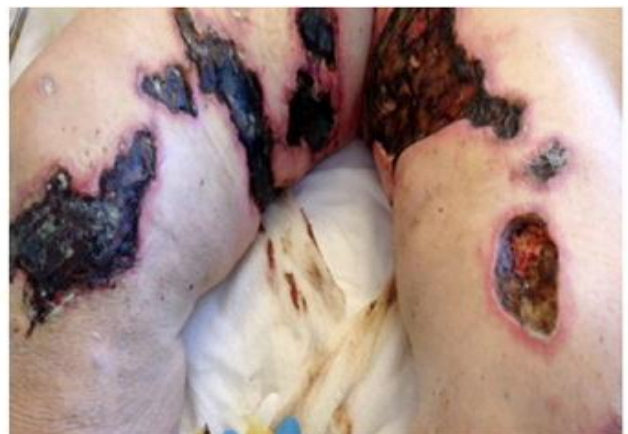

Figure 1: Early ischemic changes with livedo reticularis that later progressed to advanced ischemic necrosis, seen as stage IV ulcers and eschar formation.

Diagnosis

Calciphylaxis should be suspected in patients with painful, non-ulcerating, subcutaneous nodules or plaques; nonhealing ulcers; and/or necrosis. Additional clinical reasons to suspect the diagnosis are if review of laboratory values reveals a trend for increasing calcium phosphate product and parathyroid hormone (PTH) levels over the preceding several months and/or concurrent warfarin use. For most patients suspected of having Calciphylaxis, a skin biopsy is done which is the gold standard test. It is done by an experienced dermatologist or surgeon to confirm the diagnosis. Punch or telescoping biopsy (4 to 5 mm deep) from the lesion margin is a preferred approach. However, a skin biopsy is refrained in patients who have active infection, since a biopsy may invite further infection. [2]

Among patients in whom a biopsy is not performed, roentgenographic imaging modalities may support the diagnosis. Imaging modalities that have been used include plain radiographs, high-resolution computed tomography (CT) scans, mammography, and bone scans. All may distinguish calcium from surrounding non-calcium-containing radiolucent tissue. In one study, mammography was superior to CT or plain

films in revealing diffuse arteriolar calcification of an involved calciphylaxis lesion [2]. However, mammography is quite painful as it involves compressing the affected extremity between two plates. A three-phase technetium 99m methylene diphosphate bone scan may be useful in identifying CUA-associated soft-tissue calcifications. A positive scan suggests calcifications present in subcutaneous nodules or non-ulcerating lesions in viable tissue (which is capable of technetium 99m methylene diphosphate uptake). The exact sensitivity and specificity of this technique are unclear. Further studies are needed to define the role of routine bone scanning in assessing the risk and extent of CUA.

Histopathological findings

Biopsies have described the pathognomonic lesions of small arteries and arteriolar medial calcification (up to 600 micrometer) with intimal hyperplasia, inflammatory responses, endovascular fibrosis, associated panniculitis, extravascular calcium deposition, thrombosis and tissue necrosis. It helps to differentiate from medial vascular calcification that itself is pathological in renal insufficiency and arteriosclerosis that causes intimal calcification. [2,8]

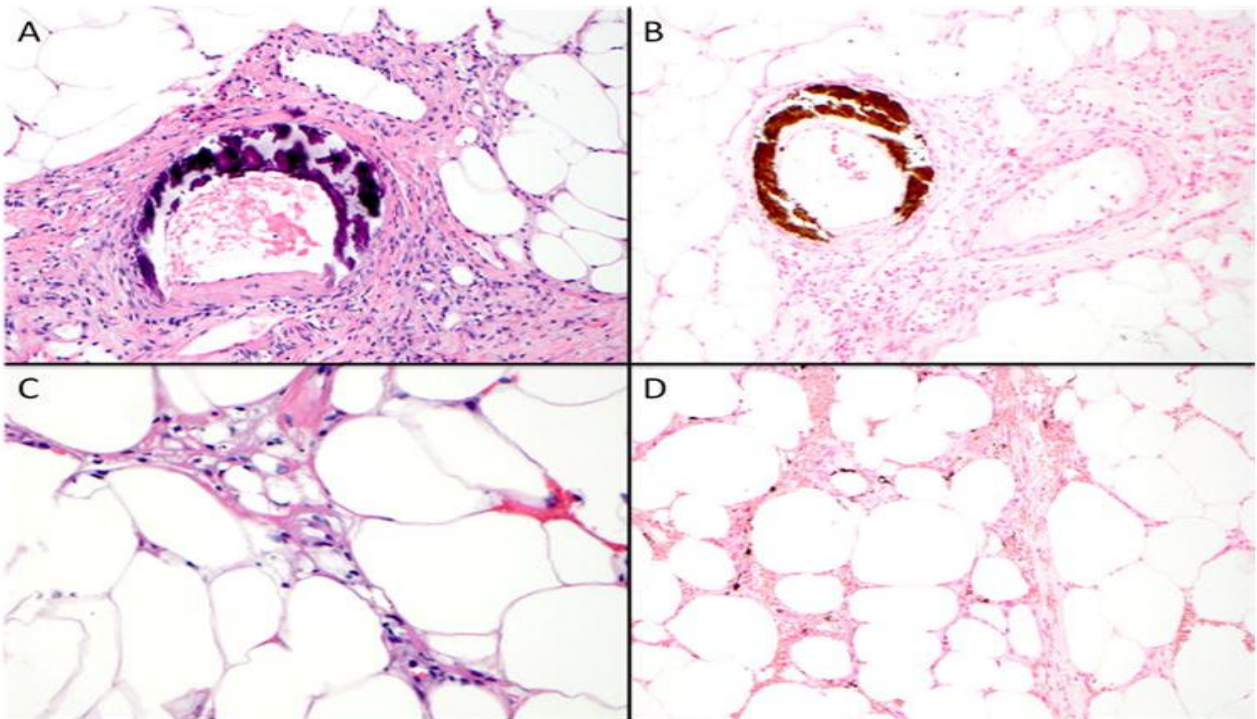


Figure 2: Course basophilic medial calcification in [A & B]. Whereas fat necrosis and septal panniculitis with subtle basophilic calcium deposit[C] and interstitial calcium deposit is seen in[D].

Treatment

❖ Since both UCA and NUC lead to extensive tissue necrosis, meticulous wound care is a mainstay for the success of therapy.

❖ Treatment of the NUC includes discontinuation of warfarin and the use of alternative anticoagulants are generally recommended to alleviate the effect on fetuin-A and matrix -Gla protein. [4]

❖ Other medicines that are discontinued includes Vitamin D, Iron, calcium supplement.

❖ Sodium Thiosulphate (STS) is given as a part of treatment; the beneficial effect of STS is thought to be part due to enhanced solubility of calcium deposits in aqueous solution. Initial experiments by Yatzidis demonstrated that calcium thiosulfate is 250, 1000, 3600, and 100,000 times more soluble in aqueous solution than calcium sulfate, citrate, phosphate, and oxalate, respectively. Hence, the administration of STS in CUA could facilitate the mobilization of calcium from the affected vessels. The mechanism for pain relief induced by STS has been hypothesized to be due to the antioxidant properties of STS, which by restoring endothelial function can enhance endothelial nitric oxide production, promoting vasodilation and reducing pain.[2,11]

❖ Hyperbaric Oxygen is also used adjunctive to STS. Hyperbaric oxygen therapy involves breathing 100% oxygen at a pressure of 2–3 times atmospheric pressure with many demonstrable effects in wound healing including reversal of wound hypoxia, upwards to level of at least 400 mmHg. Chronic, non-healing wounds such as calciphylaxis, are often hypoxic with tissue partial pressures of oxygen (pO₂) less than 40 mmHg. Tissue hypoxia contributes to poor wound healing as the formation of collagen matrix and angiogenesis are directly related to adequate oxygen tension. In addition to counteracting local wound hypoxia, hyperbaric oxygen also promotes vasoconstriction resulting in decreased edema, inhibits neutrophil adhesion and subsequent inflammatory cascade, increases neutrophil bactericidal activity and augments the bacteriostatic or bactericidal effects of certain antibiotics against anaerobic micro-organisms resulting in better control of wound infections.[13,15]

❖ Treatment of hyperphosphatemia and secondary hyperparathyroidism in patients with chronic renal disease includes bisphosphonates, newer noncalcium/nonaluminium- containing phosphate binders and cinaclet that directly acts on calcium-phosphate homeostasis. [14] If medical therapy fails in secondary and tertiary hyperparathyroidism, parathyroidectomy may be beneficial and potentially lifesaving.[16]

Conclusion

Calciphylaxis, is a serious disorder that presents with skin ischemia and necrosis and occurs most commonly, in end-stage renal disease (ESRD) patients. While in non- uremia, most cases are due to primary hyperparathyroidism, malignancies, and connective tissue diseases. The incidence of calciphylaxis may be increasing due in part to the awareness and the recognition of associated clinical signs. It remains a potential area for our understanding of pathogenesis and to find effective treatment options. The prognosis of calciphylaxis in the current date is poor.

Source of funding: Nil

Conflict of interest: None declared

References

1. Fernandez K.H., Ward D.S., 2017. Calcinosis cutis: Etiology and patient evaluation: UpToDate
2. Nigwekar S.U., Thadhani R.I. 2017. Calciphylaxis (calcific uremic arteriopathy): UpToDate
3. Kytaris V.C., Timbil S., Kalliakos D., Vaiopoulos G., Weinstein A. 2007. Calciphylaxis: A PseudoVasculitis Syndrome. *Seminars in Arthritis and Rheumatism* Vol. 36, Issue 4, Pages 264–267
4. Nigwekar S.U., Wolf M., Sterns R.H., and Hix J.K. 2008. Calciphylaxis from Nonuremic Causes: A Systematic Review. *CJASN*. 10.2215/CJN.00530108
5. Somorin A.O., Al Harbi A., Subaity Y., Zaman A.U. 2002. Calciphylaxis: case report and literature review. *Afr J Med Med Sci*. 31(2):1758.
6. Carter, T., & Ratnam, S. 2013. Calciphylaxis: A devastating complication of derangements of calcium-phosphorus metabolism – A case report and review of the literature. *Nephrology Nursing Journal*, 40(5), 431-435.
7. Gipstein R.M., Coburn J.W., Adams D.A., Lee D.B.N., Parsa K.P., Sellers A., Suki W.N., Massry S.G. 1976. A Syndrome of Tissue Necrosis and Vascular Calcification in 11 Patients With Chronic Renal Failure. *Arch Intern Med* 136:1273-1280.
8. Sowers K.M. and Hayden M.R. 2010. Calcific uremic arteriopathy Pathophysiology, reactive oxygen species and therapeutic approaches. *Oxidative Medicine and Cellular Longevity* 3:2, 109-121

9. Maroz N., Mohandes S., Field H., Kabakov Z., Simman R. 2015. Calciphylaxis in Patients With Preserved Kidney Function. *Journal of the American College of Clinical Wound Specialists*. 6, 24–8
10. Fergie B., Valecha N. and Miller A. 2017. A Case of Nonuremic Calciphylaxis in a Caucasian Woman. *Case Rep Dermatol Med*. 2017 : 6831703. doi: 10.1155/2017/6831703.
11. Araya C.E., Fennell R.S., Neiberger R.E. and Dharnidharka V.R. 2006. Sodium Thiosulfate Treatment for Calcific Uremic Arteriopathy in Children and Young Adults *Clin J Am Soc Nephrol*: 1161–1166. doi: 10.2215/CJN.01520506
12. Salmhofer H, Franzen M, Hitzl W, Koller J, Kreyman B, Fend F, Hauser, Kronberger C, Heemann U, Berr F, Schmaderer C. 2013. Multimodal treatment of calciphylaxis with sodiumthiosulfate, cinacalcet and sevelamer including longterm data. *Kidney Blood Press Res*. 2013 37(45): 34659. doi: 10.1159/000350162
13. Basile C, Montanaro A, Masi M, Pati G, De Maio P, Gismondi A. 2002. Hyperbaric oxygen therapy for calcific uremic arteriopathy: a case Series. *J Nephrol*. 15(6):67680
14. Rogers R.M., Coates P.T.H. 2008. Calcific uraemic arteriopathy: an update. 17(6): 629-34
15. Rogers N.M., Teubner D.J.O., Coates P.T.H. 2007. Calcific uremic arteriopathy: advances in pathogenesis and treatment. *Seminars in Dialysis*. Current opinion in Nephrology and Hypertension. 20(2): 150-7
16. Roy R., Lee J.A. 2011. Calciphylaxis due to hyperparathyroidism. *Endocrine Practice*. 17: 54-6
17. Hayashi M., Takamatsu I., Kanno Y., Yoshida T., Abe T. and Sato Y. 2012. A case-control study of calciphylaxis in Japanese end-stage renal disease patients. *Nephrol Dial Transplant*. 27: 1580–1584. doi: 10.1093/ndt/gfr658
18. Nigwekar S.U., Kroshinsky D, Nazarian R.M., Goverman J., Malhotra R., Jackson V.A., Kamdar M.M., Steele D. and Thadhani R.I., 2015. Calciphylaxis: Risk Factors, Diagnosis, and Treatment. *Am J Kidney Dis*., 66(1): 133–146.

Access this Article in Online	
	Website: www.darshanpublishers.com
	Subject: Medicine
Quick Response Code	

How to cite this article:

N.S. Neki, Swati Prabhakar, Alaipreet Kaur, Ashish Kumar Ludhar. (2017). Calciphylaxis - A Brief Review. *Int. J. Curr. Res. Biol. Med.* 2(8): 11-16.

DOI: <http://dx.doi.org/10.22192/ijrbm.2017.02.08.003>