
INTERNATIONAL JOURNAL OF CURRENT RESEARCH IN BIOLOGY AND MEDICINE

ISSN: 2455-944X

www.darshanpublishers.com

DOI:10.22192/ijcrbm

Volume 2, Issue 6 - 2017

Case Report

DOI: <http://dx.doi.org/10.22192/ijcrbm.2017.02.06.002>

Primary amyloidosis presenting with nephrotic syndrome: A case report and Review of literature

***Pashaura Singh Sandhu, **Alaipreet Kaur , ***N.S. Neki**

*Assistant Professor, ***Professor, Dept. of Internal Medicine, Govt. Medical College/ Guru Nanak Dev Hospital, Amritsar, India, 143001

**Medical Student, Govt. Medical College, Amritsar, India, 143001

Corresponding Author: **Dr. Pashaura Singh Sandhu**, Assistant Professor, Dept. of Internal Medicine, Govt. Medical College/ Guru Nanak Dev Hospital, Amritsar, India, 143001

E-mail: drpssandhu325@gmail.com

Abstract

Primary amyloidosis is a rare group of monoclonal plasma cell disorders, characterized by extracellular deposition of immunoglobulin light chain fibrils in multiple organs leading to progressive multiorgan dysfunction with only eight cases per million a year. It usually occurs after the age of 40 and is often rapidly progressive and fatal if untreated. We report a 50 year old male patient with chronic abdominal distension, bilateral pitting pedal edema with nephrotic range proteinuria and amyloid deposition in renal parenchyma. Immunoelectrophoresis of serum demonstrated the presence of immunoglobulin light chains of the circulating monoclonal protein with characteristic 'M' spike in lambda fraction.

Keywords: Amyloidosis (AL), Proteinuria, Renal parenchymal disease

Introduction

Amyloidosis is a generic term that refers to the extracellular tissue deposition of fibrils composed of low molecular weight subunits of a variety of normal serum proteins. These fibrils have a predominantly antiparallel β -pleated sheet configuration (noted on x-ray diffraction), and can be identified on biopsy specimens by their ability to bind congo red. Primary (AL type) amyloidosis is the most common form among all types of amyloidosis. It is an uncommon disorder and the exact incidence is unknown. In the United States, the incidence appears to be stable at approximately 6 to 10 cases per million person-years. Here we report one such rare case of primary systemic amyloidosis from our tertiary care centre.

Case Report

A 50 year old male was admitted to our hospital with history of swelling of both legs along with frothing of urine since 5 months and abdominal distension for 2 months. The swelling of both legs was insidious in onset and started around ankle region which progressed to involve lower one third of the legs. Patient also complained of abdominal distension which was insidious in onset, progressive in nature with associated stretching type of pain in whole of the abdomen. There was no history of puffiness of face, haematuria, decreased urine output, chest pain, breathlessness on exertion, palpitation, syncope. There was no history of muscle weakness, paraesthesias, vomiting, constipation, diarrhoea, dysphagia, jaundice,

hypertension, diabetes mellitus, tuberculosis, ischaemic heart disease and any other chronic illness. There was no history of smoking, alcohol intake or any drug abuse in the past.

On general physical examination, patient was moderately built and poorly nourished. He was calm, conscious and well oriented. Vitals including blood pressure was 116/70 mmHg and pulse rate was 84/min, regular. There was mild pallor and bilateral pitting oedema starting from ankle upto lower one third of legs. There was no evidence of icterus, cyanosis, clubbing, lymphadenopathy and thyroid swelling. Patient had no periorbital oedema, petechiae and echymosis. Tongue was not enlarged. Jugular venous pressure was normal. Abdominal examination revealed generalised non tender abdominal distension with shifting dullness. There was no evidence of hepatosplenomegaly. Respiratory, cardiovascular, central nervous system and locomotor system examination was unremarkable.

Laboratory investigations revealed hemoglobin of 10.9g%, total leucocyte count 11,000/mm³ and platelet count 1,16,000/mm³. Erythrocyte sedimentation rate was 110mm in 1st hour. Peripheral blood film showed normocytic normochromic anaemia. Other investigations including random blood glucose 120mg/dl, blood urea 42mg/dl, serum creatinine 1.0mg/dl and serum calcium (corrected with albumin) 8.9mg/dl, all were within normal limits. Serum sodium (136meq/dl), potassium (4.5meq/dl), phosphate (4.5meq/dl) were also normal.

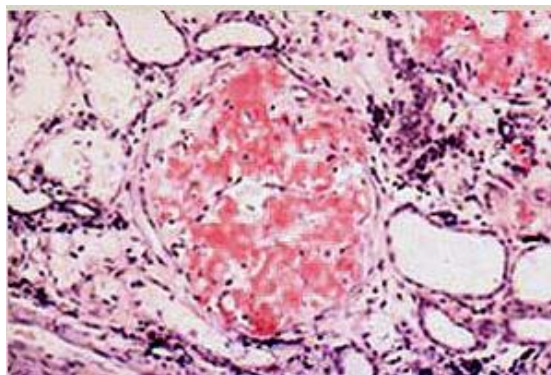


Figure 1. Amyloid deposits in kidney: red staining showing orange colour along the hyalinised areas.

Immunostaining pattern evidence of amyloid deposits in extra renal vessels and in the glomerular and extraglomerular compartments in tissue submitted for DIF studies. Serum protein electrophoresis and

Urine examination revealed 3+ dipstick proteinuria but there was no evidence of glycosuria and hematuria. 24 hr urinary protein was 6.8g/day (normal range : 50-80mg/day). Liver function tests were normal. HIV ELISA, HbsAg ELISA and anti hepatitis C serology were negative. Prothrombin time was normal. X-ray skull lateral view revealed no abnormality. Chest X-ray posteroanterior view showed minimal bilateral pleural effusion.

Electrocardiogram revealed sinus rhythm with heart rate of 84/min with evidence of low voltage graph in precordial and limb leads. 2D echocardiogram showed normal left ventricular size with concentric left ventricular hypertrophy with good systolic function and ejection fraction of 55%.

Ultrasonography of abdomen and pelvis revealed prominent kidneys (right 11cm in length and left 11.5 cm) with normal cortical thickness but echogenicity

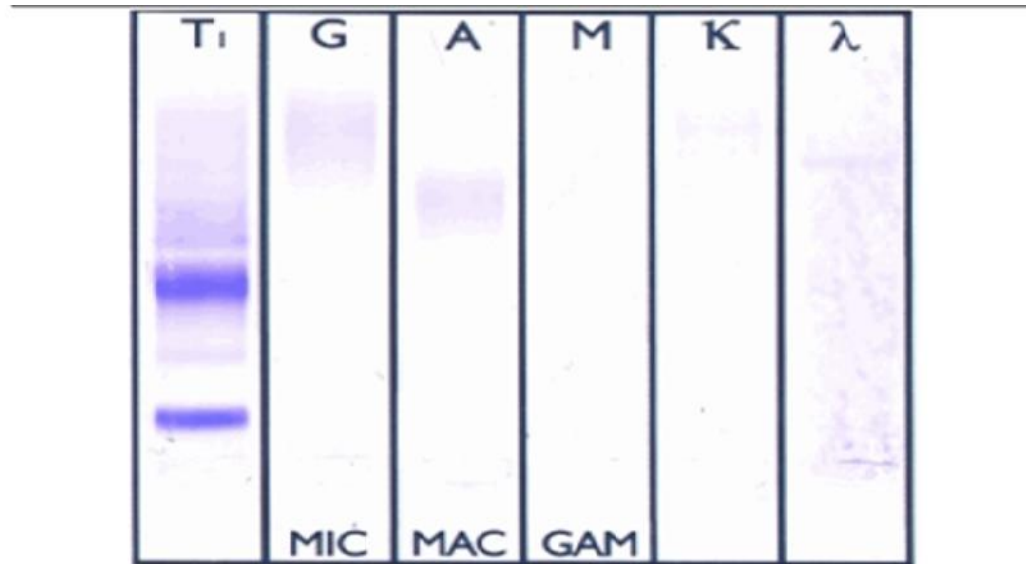
was enhanced (grade II). The corticomedullary distinction was faint with no evidence of hepatosplenomegaly.

In view of significant nephrotic range of proteinuria, enlarged kidneys, normal blood pressure and absence of other contraindications, renal biopsy was done. It showed congophillic and greenish birefringence noted in congo red stain fraction viewed under polarised light as shown in Figure 1.

immunofixation showed "M" spike in gamma globulin region (Figure 2). Bone marrow biopsy showed mild erythroid hyperplasia with no plasma cells.

A diagnosis of primary systemic amyloidosis with predominant renal involvement in the form of nephrotic syndrome with normocytic normochromic anaemia was made. Patient was initially treated with i.v. furosemide 40 mg/day, i.v. antibiotics, ACE inhibitors and i.v prednisolone 60 mg per day for 2

weeks. Patient improved symptomatically with post treatment 24 hr urinary protein 3.84gm per day and decrease in pedal swelling. As our patient was ideal candidate for hematopoietic stem cell transplant, he was discharged and referred to PGI Chandigarh for further management.



High resolution serum protein electrophoresis reveals the presence of a monoclonal gammopathy ('M' spike) in gamma globulin region.

Figure 2: Serum immunofixation electrophoresis: monoclonal gammopathy ("M" spike) seen in gamma globulin region.

Discussion

Amyloidosis is classified according to the type of amyloid protein deposited. The five main categories are primary (immunoglobulin light chain [AL]), secondary (serum protein A, produced in inflammatory conditions [AA]), hereditary (mutated transthyretin [TTR]; others), senile (wild-type TTR; atrial natriuretic peptide; others), and renal failure type (beta-2-microglobulin, not filtered out by dialysis membranes [Abeta-2M]).

Amyloidosis is further classified as localized (amyloid deposits only in a single tissue type or organ) or, most common, systemic (widespread amyloid deposition).¹

Patients with localized amyloidosis have symptoms and signs related to the affected single organ, such as hoarseness (vocal cords) or proptosis and visual disturbance (orbits). Patients with systemic amyloidosis have symptoms and signs of unexplained

medical syndromes, including heart failure (infiltrative/restrictive cardiomyopathy), nephrotic syndrome, malabsorption and weight loss, hepatic dysfunction, autonomic insufficiency, carpal tunnel syndrome (often bilateral), and sensorimotor peripheral neuropathy. Other symptoms and signs include an enlarged tongue; waxy, rough plaques on skin; contusions (including the periorbital areas); cough or dyspnea; and disturbed deglutition.¹

DIAGNOSTIC CRITERIA : The following four criteria must be met to diagnose a case of primary systemic amyloidosis (AL)³

a) Presence of an amyloid-related systemic syndrome (such as renal, liver, heart, gastrointestinal tract or peripheral nerve involvement).

b) Positive amyloid staining by Congo red in any tissue (e.g. fat aspirate, bone marrow or organ biopsy).

c) Evidence that amyloid is light chain-related established by direct examination of the amyloid (immunohistochemical staining, direct sequencing, and so on) and

d) Evidence of a monoclonal plasma cell proliferative disorder (serum or urine M protein, abnormal free light chain ratio or clonal plasma cells in the bone marrow).

Our patient fulfilled all the above mentioned four diagnostic criterias.

Kidney- Amyloidosis (AL) of the kidney is the most common and most serious feature of the disease. Grossly, the kidney may appear unchanged, or it may be abnormally large, pale, gray, and firm; in long-standing cases, the kidney may be reduced in size. Microscopically, the amyloid deposits are found principally in the glomeruli. Congo red staining is the most important tool in the diagnosis of amyloidosis.²

Low voltage waves in the limb and the precordial leads are the most common ECG finding in cardiac amyloidosis and are present in over 50% of patients with Primary Amyloidosis. 2-D Echocardiography finding is left ventricular hypertrophy.^{4,5,6,7} Similar findings on ECG and 2D-Echocardiography were observed in our case.

Many centres all over the world currently use high dose chemotherapy with stem cell transplantation as the standard/basic treatment for patients with AL. The patients have to be carefully examined for eligibility for this procedure in order to minimize high peri transplant mortality. Patients at very high risk are those older than 65 years, with more than two affected organs, with significant hypotension (systolic blood pressure < 90 mm Hg) or syncopes, with ejection fraction of left ventricle >45% or thickness of interventricular septum 6 -15 mm.⁸

Our case was unique in the terms that renal medullary disease was present with only nephrotic range proteinuria but normal renal functions. Also there was no significant cardiac involvement. As he was an ideal candidate for haematopoietic stem cell transplantation, so he was discharged and referred to PGIMER, Chandigarh for further management.

To the best of our knowledge, probably this is the first case report from this part of India. Hence the case report.

Conclusion

Primary systemic amyloidosis should always be considered in any patient >40 yr old who presents with nephrotic range proteinuria with multiple organ involvement and biopsy proven primary amyloidosis so that early institution of treatment will reduce the morbidity. Clinicians should always be aware of this clinical entity as newer treatment options including stem cell transplant especially when given to eligible candidates decrease mortality and increase the quality of life.

Source of funding: Nil

Conflict of interest: None declared

References

1. Papadakis M, McPhee S, Rabow M. Current medical diagnosis & treatment 2015. 54th ed. McGraw-Hill Education; 2015 ; 13: 528
2. Kumar V, Abbas A, Aster JC. Robbins basic pathology. 9th ed. Philadelphia:Elsevier Saunders; 2013;4:154-8
3. Rajkumar SV, Dispenzieri A, Kyle RA. Monoclonal gammopathy of undetermined significance, Waldenstrom macroglobulinemia, AL amyloidosis, and related plasma cell disorders: diagnosis and treatment. Mayo Clin Proc. 2006;81:693-703
4. Murtagh B, Hammill SC, Gertz MA, Kyle RA, Tajik AJ, Grogan M. Electrocardiographic findings in primary systemic amyloidosis and biopsy-proven cardiac involvement. Am J Cardiol. 2005; 95: 535-37.
5. Rahman JE, Helou EF, Gelzer-Bell R, et al. Noninvasive diagnosis of biopsy-proven cardiac amyloidosis. Am J Cardiol. 2004; 43: 410-15.
6. Carroll JD, Gaasch WH, McAdam KP. Amyloid cardiomyopathy: characterization by a distinctive voltage/mass relation. Am J Cardiol. 1982; 49: 9-13.
7. Simons M, Isner JM. Assessment of relative sensitivities of noninvasive tests for cardiac amyloidosis in documented cardiac amyloidosis. Am J Cardiol. 1992; 69: 425-427

8. Mollee PN, Wechalekar AD, Pereira DL, Franke N, Reece D, Chen C, Stewart AK: Autologous stem cell transplantation in primary systemic amyloidosis: the impact of selection criteria on outcome. Bone Marrow Transplant 2004;33:271–77.

Access this Article in Online	
	Website: www.darshanpublishers.com
	Subject: Medicine
Quick Response Code	

How to cite this article:

Pashaura Singh Sandhu, Elaipreet Kaur, N.S. Neki. (2017). Primary amyloidosis presenting with nephrotic syndrome: A case report and Review of literature. Int. J. Curr. Res. Biol. Med. 2(6): 8-12.

DOI: <http://dx.doi.org/10.22192/ijcrbm.2017.02.06.002>