
INTERNATIONAL JOURNAL OF CURRENT RESEARCH IN BIOLOGY AND MEDICINE

ISSN: 2455-944X

www.darshanpublishers.com

DOI:10.22192/ijcrbm

Volume 2, Issue 6 - 2017

Case Report

DOI: <http://dx.doi.org/10.22192/ijcrbm.2017.02.06.004>

Rapidly vanishing lung pseudotumor in a case with liver abscess

Nishanth .P.S¹, N C Kajal², Sandeep Gupta³, Daljeet Singh⁴, Srijna Rana⁵
Amarendra Kumar Shukla⁶

¹Junior Resident Chest and TB Department, Government Medical College, Amritsar, India

²Professor, Chest and TB department, Government Medical College, Amritsar, India

³Assistant Professor, Chest and TB department, Government Medical College, Amritsar, India

⁴Junior Resident, Chest and TB department, Government Medical College, Amritsar, India

⁵Junior Resident, Chest and TB department, Government Medical College, Amritsar, India

⁶Junior Resident, Chest and TB department, Government Medical College, Amritsar, India

Corresponding Author : Dr. Nishanth.P.S

Room no: 51, F-Block hostel, Government Medical College -Amritsar

Circular road, Amritsar-143001 Mobile no. +918054741142

E- mail: nishanthps88@gmail.com

Abstract

Rapidly vanishing lung pseudotumor (phantom tumor) refers to the transient well-demarcated accumulation of pleural fluid in the interlobar pulmonary fissures. Most frequently their appearance is associated with congestive heart failure, but also other disorders like hypoalbuminemia, renal insufficiency or pleuritis. Its rapid disappearance in response to the treatment of the underlying disorder is a classical feature of this clinical entity. We report a case of 45 year old male who presented with breathlessness and on radiological examination was found to have fluid in horizontal fissure which resorbed with appropriate treatment.

Keywords: Pseudo tumour, vanishing tumour, Congestive heart failure, loop diuretics

Introduction

Localized interlobar effusions in congestive heart failure (phantom or vanishing lung tumor/s) is/are uncommon but well known entities ¹⁻³. Due to the small number of reported cases, the incidence is difficult to estimate. In 1928, Stewart was the first one to report this entity as “interlobar hydrothorax” ⁴. The term phantom tumor may be used to describe a well-demarcated opacity resulted from pleural effusion. Phantom tumors are commonly associated with congestive heart failure causing transudative pleural effusion within pulmonary fissures. This may bring about inaccurate invasive diagnostic interventions.

The name originates from its frequent resemblance to a tumor on the CXR and from its tendency to vanish after appropriate management of heart failure. Phantom tumors predominantly occur in men in the right hemithorax, with three-quarters of the reported cases in the right transverse fissure and less frequently in the oblique fissure. Simultaneous occurrences in both fissures were reported in about one-fifth of cases while in the left hemithorax were described only sporadically. Pathogenesis, as per mostly supported hypothesis - adhesions and obliteration of the pleural space around the edge of the fissure which is due to

pleuritis. Phantom tumors arise whenever the transudation from the pulmonary vascular space exceeds resorptive ability of the pleural lymphatics. However, this atypical intra-fissural distribution of pleural effusions can also be explained by local increase in elastic recoil by adjacent, partially atelectatic lung that yields a “suction cup” effect and favors loculation of liquid even in the absence of pleural adhesions.^{5,6}

Case Report

We had a 45 year old male who presented with breathlessness, right sided chest pain and dry cough for 3 weeks. On examination the patient was dyspnoeic, accessory muscles of respiration were working and had difficulty in lying in the right lateral position.

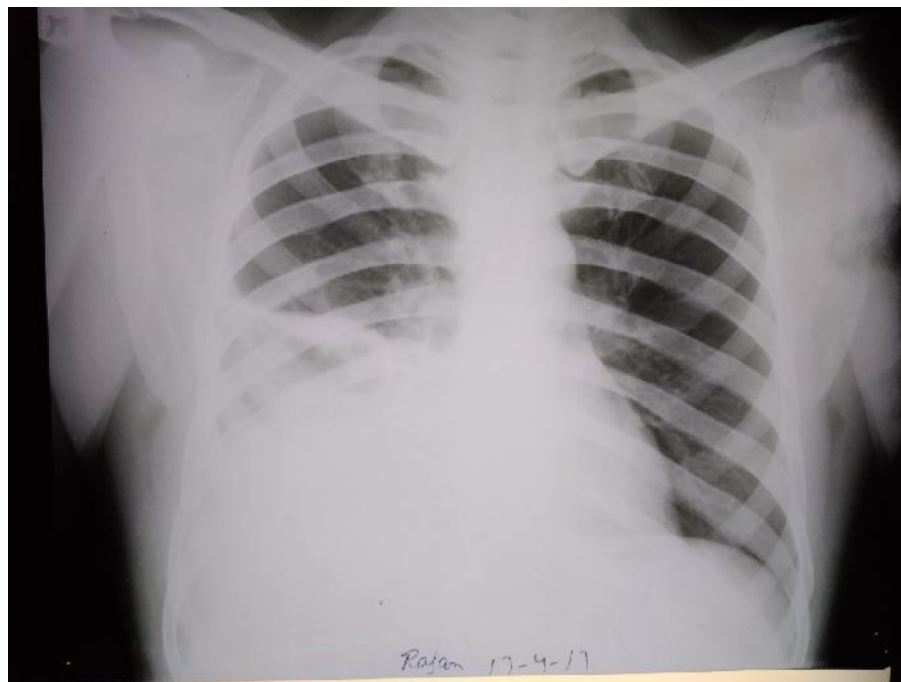
On general physical examination patient was thin built and moderately nourished. Thyroid gland not palpable. The vitals of the patient were BP-140/90 mm Hg, Pulse rate – 88/min, Respiratory rate – 18/min. No

superficial lymph nodes were palpable, and chest, abdominal, and neurological findings were unremarkable. On Respiratory system examination, shape of the chest was asymmetrical. Movements of chest decreased on the right side of the chest, trachea left shift, respiratory rate 28 /min. On Palpation- Patient was febrile with tenderness over right side chest, Chest movement & expansion decreased right side of chest, Vocal fremitus – decreased on right side of chest in the mammary area. Percussion note was dull on right side of chest mammary area. On Auscultation breath sounds were decreased on right side of chest in mammary area with no added sounds. Breathing on the left side is vesicular without any accompaniments.

Hematology and blood chemistry were within normal limits, HIV – non reactive.

Chest xray shows (Fig 1) Homogenous opacity in the left lower zone along with fluid in the horizontal fissure appearing as a spindle shaped opacity.

Figure 1

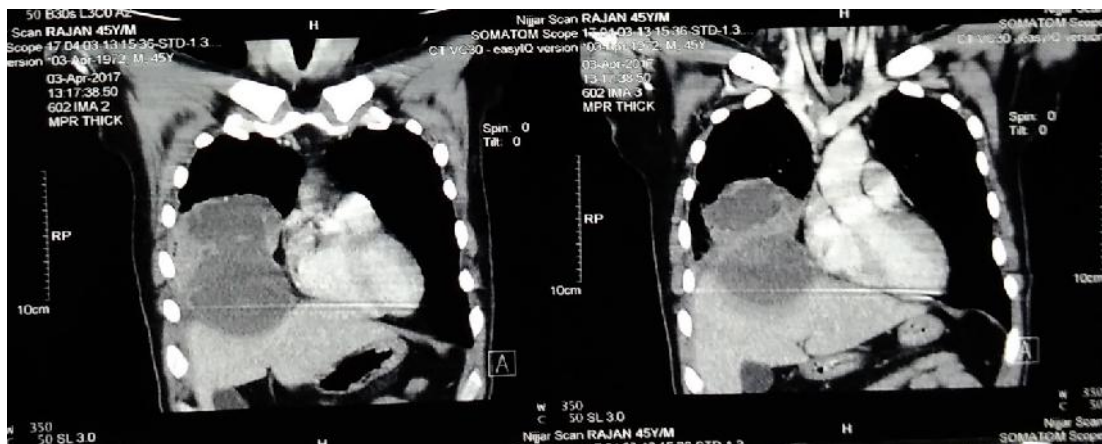

CT scan (Fig 2) shows moderate right sided pleural collection showing encystment along horizontal fissure. A bilocular relatively ill marginated fluid density lesion surrounded by air space opacification in the region of right middle lobe anteriorly with one of its locules extending inferiorly and indenting the hepatic contour with poorly appreciated dome of

diaphragm with trans diaphragmatic rupture. Mediastinal lymphadenopathy is also seen.

USG Abdomen showed liver abscess. Pulmonary ultrasound examination confirmed pleural fluid in the horizontal fissure.

Figure 2



Pleural fluid analysis showed an exudative picture. After full investigations we found Liver abscess which has ruptured into the lung parenchyma with fluid in the horizontal fissure. All the investigations were done to rule out transudative causes of pleural effusion.

Discussion

Phantom tumors predominantly occur in men in the right hemithorax, with three-quarters of the reported cases within the right transverse fissure and less frequently within the oblique fissure. Simultaneous occurrences in both fissures were reported in about one-fifth of cases while in the left hemithorax were described only sporadically [6,7].

The right-sided predilection of phantom tumor is best explained by the greater hydrostatic pressure existing on this side in comparison with left in congestive heart.

failure which results in impaired venous and lymphatic drainage causing loculation of fluid⁸. Differential diagnosis of loculated pleural effusions within the fissure includes - A. Transudates - left ventricular failure or renal failure,

B. Exudates - parapneumonic pleural effusions, malignant pleural effusions, and benign asbestos-related pleural effusions, hemothorax, chylothorax, and fibrous tumors originating from the visceral pleura of the interlobar fissure.⁶

In right base pathology, infection usually spreads to the lungs by extension of a liver abscess. Infection may pass to the thorax directly from the primary

intestinal lesion through hematogenous spread, however. Lymphatic spread is one possible route. The lung is the second most common extraintestinal site of amebic involvement after the liver. Usually the lower lobe, and sometimes the middle lobe of the right lung, are affected, but it may affect any lobe of the lungs. The patient develops fever and right upper quadrant pain that is referred to the tip of the right shoulder or in between the scapula. Hemoptysis is common. The diagnosis of thoracic involvement is suggested by the combination of an elevated hemi diaphragm (usually right), hepatomegaly, pleural effusion, and involvement of the right lung base in the form of haziness and obliteration of costophrenic and costodiaphragmatic angles. Infection is usually extended to the thorax by perforation of a hepatic abscess through the diaphragm and across an obliterated pleural space, producing pulmonary consolidation. The differential diagnosis must include all causes of interlobular effusions i.e pneumonia, tuberculosis, infarction, together with more rarer entities. In the present case clinic radiological findings were in favour of liver abscess and that abscess spread to thorax causing involvement of pleura and lung resulting development of consolidation with synpneumonic effusion and along with fluid in horizontal fissure (phantom tumour) (Figure 1). Aspiration of pleural fluid was done and it was found to be exudative in nature. As the most common cause of phantom tumor is transudative, so all the investigations to rule out this etiology was done. After appropriate management, chest xray revealed complete resolution of the observed oval/oblique tumour like image (Figure 2).

Conclusion

So in the present case we have concluded that the pseudotumour or phantom tumour may not be always found in cases of transudative pathologies. As in our case, the etiology was liver abscess spreading into lung parenchyma developing phantom tumour, a rare entity found in literature. A high level of suspicion should be kept in mind for diagnosing cases other than transudative causes.

References

1. W. I. Gefter, K. R. Boucot, and E. W. Marshall, "Localized interlobar effusion in congestive heart failure; vanishing tumor of the lung," 1950; 2(3): 336–343,
2. C. E. Millard, "Vanishing of phantom tumor of the lung; localized interlobar effusion in congestive heart failure," Chest. 1971 : 59(6): 675–677.
3. E. Oliveira, P. Manuel, J. Alexandre, and F. Girão, "Phantom tumour of the lung," The Lancet.2012: 380(9858): 2028
4. D. E. Bedford and J. L. Lovibond, "Hydrothorax in heart failure," British Heart Journal1941: 3(2): 93–111,
- 5.K. P. Buch and R. S. Morehead, "Multiple left-sided vanishing tumors," Chest, , 2000: 118(5): 1486–1489
6. F. G. Fleischner, "Atypical arrangement of free pleural effusion," Radiologic Clinics of North America. 1963; 1: 347–362
- 7.B. M. Haus, P. Stark, S. L. Shofer, and W. G. Kushner, "Massive pulmonary pseudotumor," Chest. 2003;124(2):758–760,
- 8.P. Stark and A. Leung, "Effects of lobar atelectasis on the distribution of pleural effusion and pneumothorax," Journal of Thoracic Imaging. 1996 ; 11 (2): 145–149

Access this Article in Online	
	Website: www.darshanpublishers.com
	Subject: Medical Sciences
Quick Response Code	

How to cite this article:

Nishanth .P.S, N C Kajal, Sandeep Gupta, Daljeet Singh, Srijna Rana, Amarendra Kumar Shukla. (2017). Rapidly vanishing lung pseudotumor in a case with liver abscess. Int. J. Curr. Res. Biol. Med. 2(6): 20-23.
DOI: <http://dx.doi.org/10.22192/ijrbm.2017.02.06.004>