

---

# INTERNATIONAL JOURNAL OF CURRENT RESEARCH IN BIOLOGY AND MEDICINE

ISSN: 2455-944X

[www.darshanpublishers.com](http://www.darshanpublishers.com)

DOI:10.22192/ijcrbm

Volume 2, Issue 11 - 2017

---

Original Research Article

DOI: <http://dx.doi.org/10.22192/ijcrbm.2017.02.11.008>

## Assessment of neurological manifestations in HIV positive patients

Krishan Oberoi<sup>\*</sup>, Neeraj Joshi<sup>\*\*\*\*</sup>, Shiv Charan<sup>\*\*</sup>, NS Neki<sup>\*\*\*</sup>, Gaurav Joshi<sup>\*\*\*\*\*</sup>,  
Gagandeep Singh<sup>\*\*\*\*\*</sup>, Rajvir Singh<sup>\*\*\*\*</sup>, Akanksha Sandhu<sup>\*\*\*\*</sup>,  
Gurminder Multani<sup>\*\*\*\*</sup>, Gagandeep Shergill<sup>\*\*\*\*</sup>, Narender Meena<sup>\*\*\*\*</sup>,  
Deepali Kaushal<sup>\*\*\*\*</sup>, Inderjot Kaur<sup>\*\*\*\*</sup>, Priya Sharma<sup>\*\*\*\*</sup>, Deepak Rana<sup>\*\*\*\*\*</sup>.

<sup>\*</sup>Associate Professor, <sup>\*\*</sup>Professor, <sup>\*\*\*</sup>Professor and Head of Department Medicine, <sup>\*\*\*\*</sup>Junior Resident Department of Internal Medicine, Govt. Medical College & Guru Nanak Dev Hospital, Amritsar, Punjab, India, 143001.

<sup>\*\*\*\*\*</sup> Head Of Department Pharmacy Practice Pharma D, Laureate Institute Of Pharmacy, Kangra, Himachal Pradesh, India, 177101.

<sup>\*\*\*\*\*</sup> Research Associate, Department of Neurology, University Hospitals Cleveland Medical Center, Cleveland, Ohio (USA)

<sup>\*\*\*\*\*</sup> Junior Resident, Department of Radiology. Govt. Medical College and Guru Nanak Dev Hospital, Amritsar, India

Corresponding Author: **Neeraj Joshi**, Junior Resident, Dept.of Medicine, Govt. Medical College, Amritsar  
E-mail: [neerajjoshi941@gmail.com](mailto:neerajjoshi941@gmail.com)

---

### Abstract

**Background:** Nervous system involvement is one of the catastrophic target of human immunodeficiency virus (HIV) infection. In spite of adequate ART (antiretroviral therapy), HIV infected individuals still experience neurological diseases. At least 40% HIV-infected patients develop neurological symptoms during the course of their illness and in 10-20% of the patients, the presence of a neurological disease is the first manifestation of symptomatic HIV infection.

**Aims and Objectives:** To illuminate the spectrum of neurological involvement in patients with HIV infection at Govt Medical College & Hospital Amritsar (Punjab). We evaluated various neurological manifestations of HIV including opportunistic infections (OPIs) and non-opportunistic infections (nonOPIs).

**Settings and Design:** This was an observational study conducted at Govt Medical College & Hospital Amritsar (Punjab) over a period of 1 years from June 2016 to July 2017.

**Materials and Methods:** The study included a total of 100 HIV seropositive patients of both genders, of age >18 years, attending the ART centre, medicine OPD, admitted in medicine ward with neurological manifestations, at Govt Medical College & Hospital Amritsar (Punjab) were studied for clinical parameters, laboratory investigations and imaging.

**Results:** A total of 100 patients admitted with HIV infection, of which 44 patients (44%) presented with neurological manifestations were enrolled in the study. The most common age group affected was 31 to 40 years (45.4%), males were affected more than females (63.6% male patients, 36.3% female patients) and most of the patients were from rural (72.73%) areas of Amritsar. Fever (59.09%) was the most common feature. Headache in 22 patients (50%) was most common neurological complaint followed by altered sensorium in 19 patients (43%) and focal neurological deficit in 15 patients (34.09%). Tubercular meningitis in 13 patients (59.09%) followed by cryptococcal meningitis in 6 patients (27.27%) was most common cause of headache. Most common cause of altered sensorium was tubercular meningitis in 7 patients (36.8%). Tuberculosis (59.26%) was most common opportunistic infection followed by cryptococcal meningitis (25.93%) and toxoplasmosis in (14.81%) patients. Non-opportunistic neurological manifestations were present in 16 patients (36.36%), out of which cerebral infarcts in 9 patients

(56.25%) followed by HIV myelopathy in 2 patients (12.5%), primary CNS lymphoma in 2 patients (12.5%), sub-acute combined degeneration of spinal cord, peripheral neuropathy, sensory ataxia in 1 patient (6.25%) each.

**Conclusion:** We found a high prevalence of neurological manifestations in HIV seropositive patients (44%) in this setting. Tubercular meningitis was the most common secondary infection seen in HIV patients followed by Cryptococcal meningitis. The most common non-infectious lesions included cerebrovascular events, followed by HIV myelopathy and neoplasms. Neuropathies were the least common neurological manifestations in patients with HIV infection. There must be a high index of suspicion for neurological manifestations in HIV patients presenting with neurological complaints, as most of these opportunistic infections are treatable.

**Keywords:** Nervous system, HIV, OPIs, nonOPIs cryptococcal meningitis.

## Introduction

India has the third largest HIV (human immunodeficiency virus) epidemic in the world. In 2015, HIV prevalence in India was around 0.26%.<sup>1</sup> AIDS (acquired immunodeficiency syndrome) was first described in 1981 and first few cases were recognized because of unusual clustering of diseases such as *Pneumocystis jiroveci* pneumonia in young homosexual men in Los Angeles and New York, USA.<sup>2</sup> In 1986, the first known case of HIV in India was diagnosed by Dr. Suniti Solmon amongst female sex workers in Chennai.<sup>3</sup>

The total number of HIV positive cases in Punjab (till October 2015) is almost 49,000 with Amritsar topping the chart with almost 13,000 cases followed by Patiala, Ludhiana and Jalandhar. Over the years, from 2008 onwards, there is a decrease in HIV positivity. In 2008, the total number of people tested for HIV was over 1.67 lakh of which almost 5,000 were found positive. The positivity percentage was 2.96. It gradually reduced to 2.34% in 2009 and then to 1.96 (2010), 1.55 (2011), 1.13 (2012), 0.9 (2013) and then dropped to 0.87 last year when of the total 5.1 lakh people tested, only 4,500 tested positive.<sup>4</sup>

In spite of adequate ART (anti retroviral therapy), HIV infected individuals still experience neurological diseases. A variety of factors contributing to it, which includes lack of complete control of HIV replication in brain, production of HIV proteins that may be neurotoxic, low CD4+ T cell nadir, chronic immune activation, comorbidities such as drug abuse, and the potential for neurotoxicity of certain of the antiretroviral drugs. HIV has been demonstrated in the brain and CSF of infected individuals with and without neurological abnormalities. The precise mechanisms whereby HIV enters the brain are unclear, however, they are thought to relate, at least in part, to the virus-infected and immune activated

macrophages to induce adhesion molecules such as E-selectin and vascular cell adhesion molecule 1 (VCAM-1) on brain endothelium. Once HIV enters the brain due to pressures of local environment, it evolves to develop distinct sequences in the env, tat, and TLR genes. These unique sequences have been associated with neurological dysfunction; however it is unclear if they are causal. The initial "seeding" of the nervous system by HIV-1 is usually asymptomatic, although acute aseptic meningitis, encephalitis, and inflammatory polyneuropathy have all occurred in this setting.<sup>6</sup>

Nervous system complications can occur during all stages of HIV infection, whether early or late, can affect any part of nervous system. Neurological involvement causes significant morbidity and mortality in HIV infected individuals. Various Central nervous system (CNS) manifestations include Meningitis, Seizure, Dementia, Space occupying lesions, Progressive multifocal leucoencephalopathy (PML), Stroke, Extra pyramidal Syndromes, Myelopathy, Myopathies and Neuropathies. HIV associated cognitive disturbances; myelopathy, CNS lymphoma and Progressive Multifocal Leucoencephalopathy (PML) are significantly less common compared to the west. The type of neurological involvement depends on the stage of immune dysfunction. During early stages of immune dysfunction manifestations like Bell's palsy and Guillain-Barre syndrome are common while during late stages more severe disorders comprising of neurological infections such as cryptococcal meningitis, tubercular meningitis, cytomegalovirus (CMV) encephalitis, PML, HIV Dementia and polyradiculopathy appears.<sup>7</sup>

An improvement in immune status with the initiation of highly active antiretroviral therapy (HAART) results in new group of disorders called the immune reconstitution syndromes. Neurologic immune reconstitution inflammatory syndrome (NeuroIRIS) is a newly recognized complication of combination antiretroviral therapy.<sup>8</sup>

## Materials and Methods

### Study Population

The study included the HIV positive patients attending the ART Centre medicine OPD, admitted in medicine ward having neurological complaints.

### Inclusion Criteria

1. All HIV positive patients admitted in medicine and patients coming to ART Centre having neurological symptoms and/or sign.
2. Patients should give written consent for inclusion in study.
3. Age more than 18 years.

### Exclusion Criteria

1. Patients with history of neurological diseases like Cerebrovascular accidents, epilepsy prior to diagnosis of HIV.
2. Patients suffering from diabetes mellitus.
3. H/O drug abuse like narcotics, sedatives and hypnotic.

### Methodology

Patients were assessed clinically by relevant history, general physical examination and systemic examination after taking consent and specific investigations (CSF analysis, NCCT Head, MRI BRAIN) were undertaken to establish the clinical profile whenever required.

### Results

Table 1 showing out of 100 patients, 44(44%) patients had neurological complaints.

Table no. 1 Screening of patients (n=100)

	No. of Patients	Percentage
Total Patients	100	100
Neurological manifestation	44	44

Table no.2 Age distribution (n=44)

Age Groups (Years)	No. of Patients	Percentage
21-30	6	13.64
31-40	20	45.45
41-50	13	29.55
51-60	4	9.09
61-70	1	2.27
Total	44	100.00

**Figure: 2**

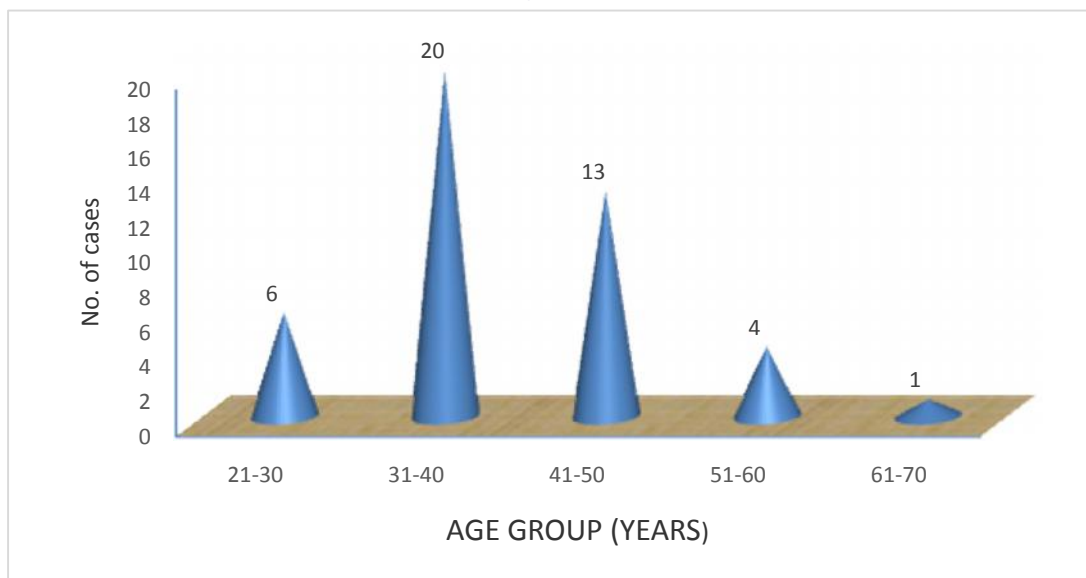


Table 2 showing age distribution, having maximum number of patients in the age group of 31- 40 years (45%).

**Table no. 3 Sex distribution (n=44)**

Sex	No. of Patients	Percentage
Male	28	63.64
Female	16	36.36
Total	44	100.00

**Figure: 3**

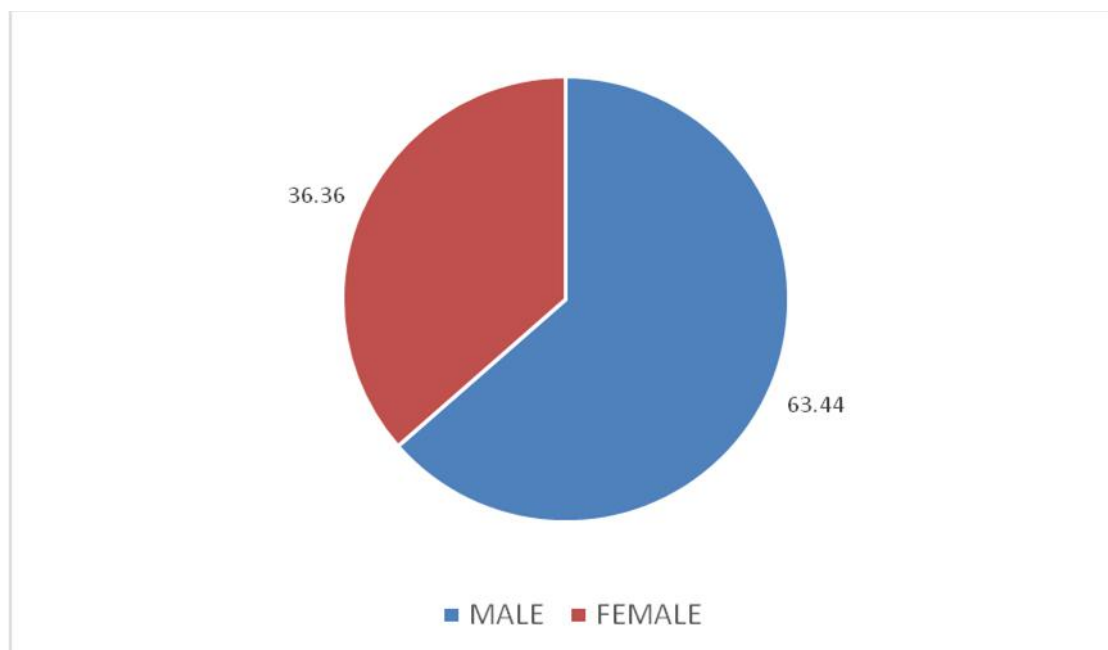


Table 3 showing sex distribution having 28(63%) male and 16(36%) females patients in the study.

Table no. 4 Demographic distribution (n=44)

Demographic	No. of Patients	Percentage
Rural	32	72.73
Urban	12	27.27
Total	44	100.00

Figure: 4

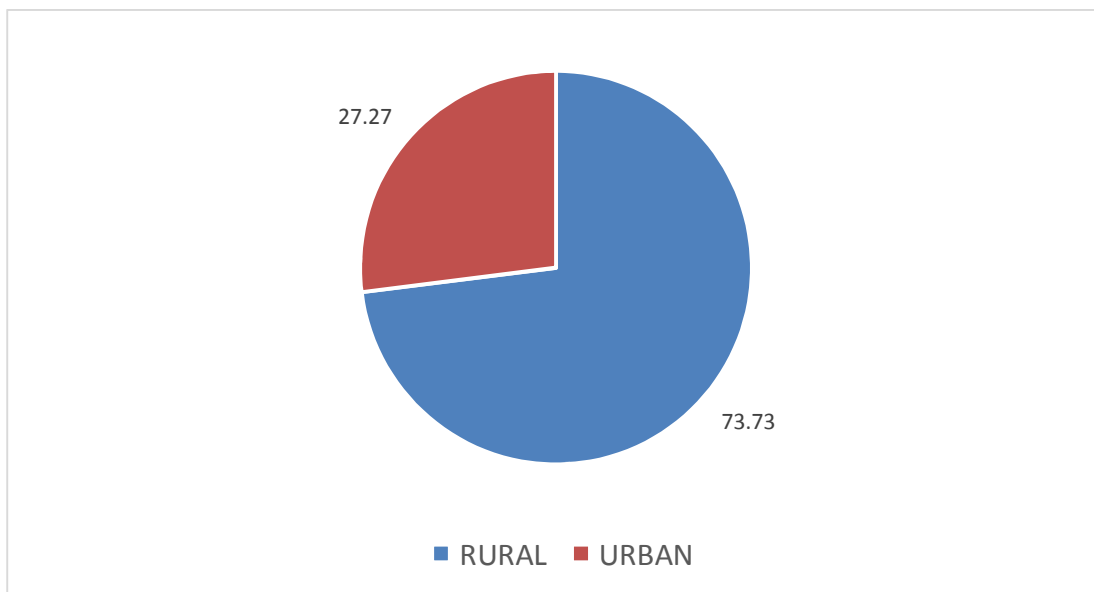


Table 4 showing demographic distribution having 32 patients (72%) from rural area and 12 patients (27%) from urban area.

Table no. 5 Clinical features (n=44)

Symptom	No. of Patients	Percentage
Fever	26	59.09
Weight loss	9	20.45
Cough	7	15.90
Diarrhoea	5	11.36

Figure: 5

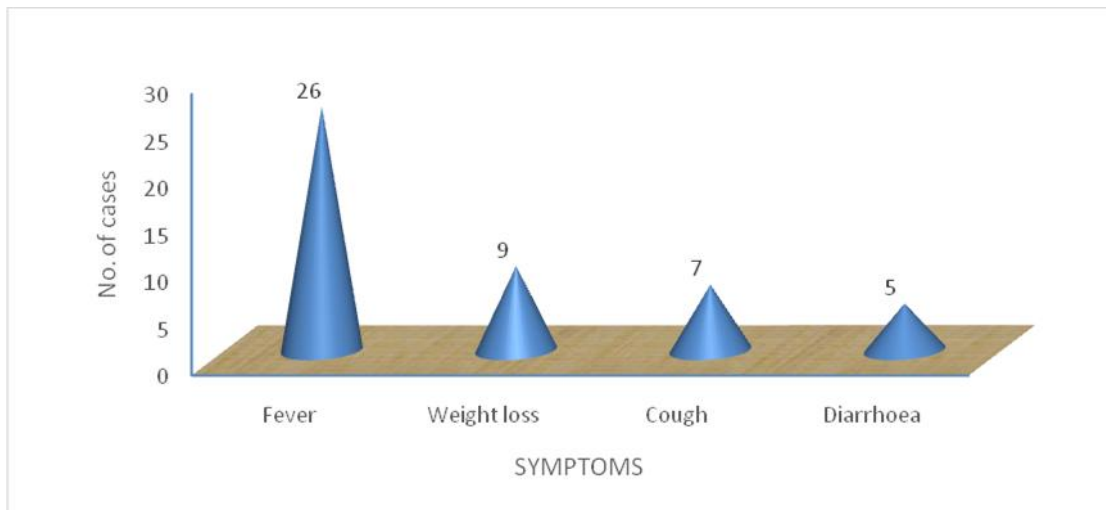


Table 5 showing clinical features in which fever was most common in 26 patients (59%) at the time of presentation, weight loss in 9 patients (20.45%). cough

with or without expectoration which was present in 7 patients (15.9%). 5 patients (11.3%) complained of diarrhoea.

Table no. 6 Neurological symptoms at presentation (n=44)

Symptom	No. of Patients	Percentage
Headache	22	50.00
Altered sensorium	19	43.18
Focal Neurological Deficit/Weakness	15	34.09
Seizures	4	9.09
Peripheral neuropathy	1	2.27
Gait ataxia	1	2.27

Figure:6

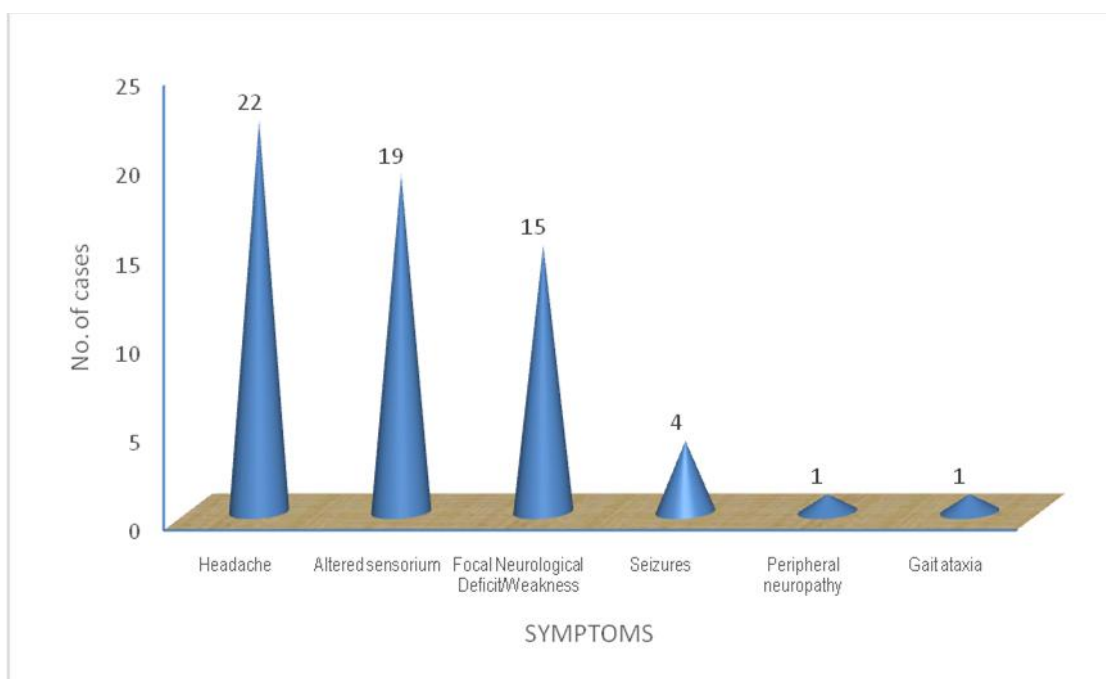


Table 6 showing neurological symptoms. Headache was present in 22 patients (50%). Altered sensorium was present in 19 patients (43.18%). 15 patients (34%)

were having focal neurological deficit, 4 patients (9%) with seizures and one patient with gait ataxia and one patient with peripheral neuropathy.

Table no. 7 Neurological examination findings (n=44)

Clinical Finding	No. of Patients	Percentage
Altered Sensorium	19	43.18
Features of meningeal irritation	20	45.45
Focal neurological deficits / Weakness	15	34.09
Ataxia	1	2.27
Peripheral neuropathy	1	2.27

Figure: 7

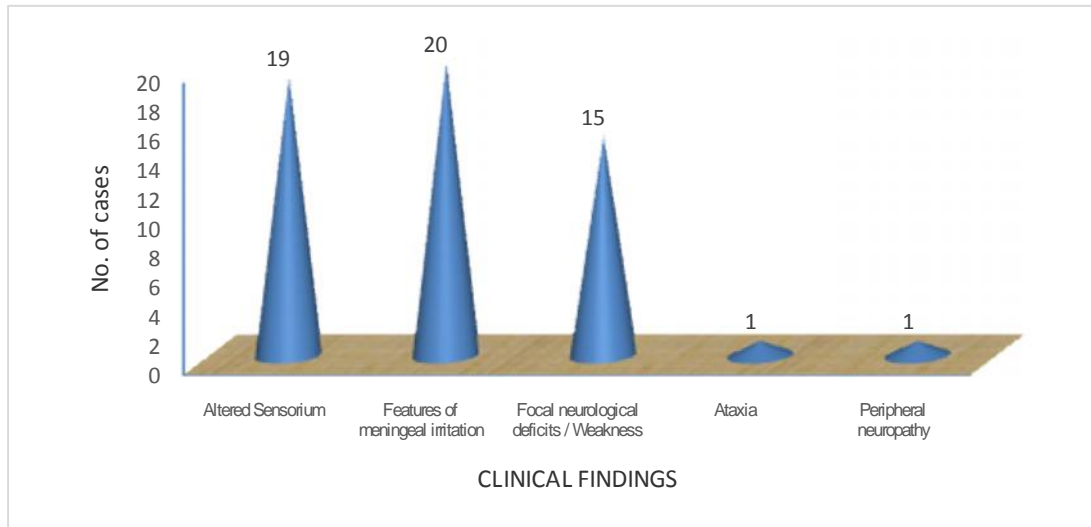


Table 7 showing neurological examination findings. The most common neurological finding on examination was meningeal irritation in 20 patient (45.4%) followed by altered sensorium in 19 patients

(43.18%), focal neurological deficit (weakness) was present in 15 patients (34%) patients, ataxia and peripheral neuropathy was present in 1 patient (2.27%) each.

Table no. 8 Causes of headache (n=22)

Cause of headache	On ART		Not On ART		Total	
	No.	%	No	%	No	%
TBM	6	13.64	10	22.73	16	59.26
Cryptococcal meningitis	4	9.09	3	6.82	7	25.93
Toxoplasmosis	1	2.27	3	6.82	4	14.81
Total	11	25.00	16	36.36	27	100.00

Figure: 8

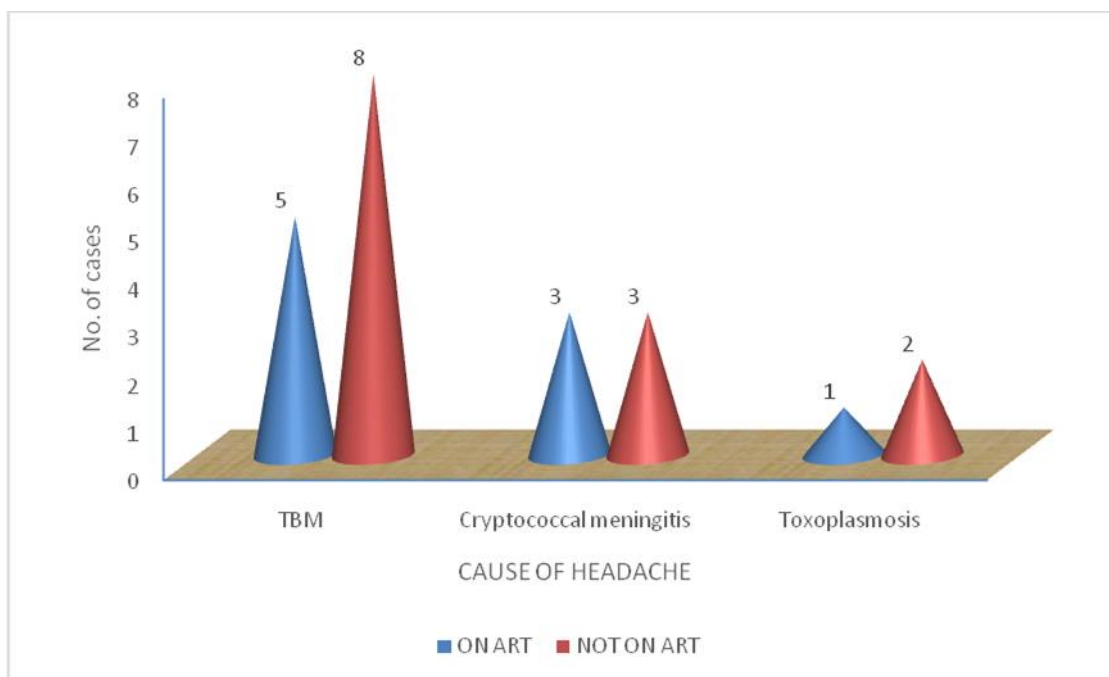


Table 8 showing causes of headache. Out of 44 patients 22 patients (50%) were having headache at the time of admission. Out of these 22 patients, 13 patients (59.09%) were having headache due to TB

meningitis, in 6 patients (27.27%) due to cryptococcal meningitis, in 3 patients (13.63%) due to toxoplasmosis.

Table no. 9 Causes of altered sensorium (n=19)

Cause of altered sensorium	On ART		Not On ART		Total	
	No.	%	No.	%	No.	%
Tubercular meningitis	1	5.26	6	31.57	7	36.8
Cryptococcal meningitis	3	15.7	2	10.52	5	26.3
Toxoplasmosis	1	5.26	3	15.78	4	21.1
CNS lymphoma		0.00	1	5.26	1	5.3
Seizures		0.00	2	10.52	2	10.5
Total	5	26.31	14	73.7	19	100.0

Figure: 9

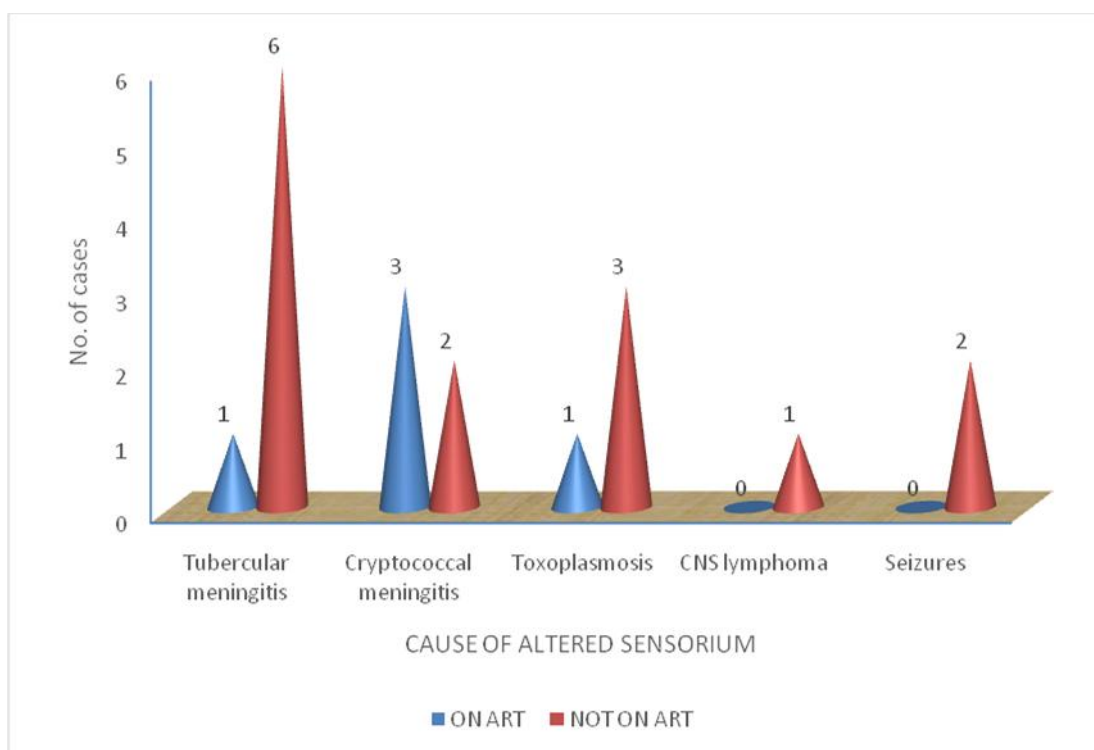


Table 9 showing causes of altered sensorium. Out of 44 patients 19 patients (43%) were having altered sensorium at the time of admission. In 7 patients (36.8%) cause was tubercular meningitis followed by,

5 patients (26.3%) were having cryptococcal meningitis. 4 patients (21.1%) patients were having toxoplasmosis 1(5.26%) patient was having lymphoma.



Table no. 10 CD4 Counts of the patients (n=44)

CD4 count	On ART		Not On ART		Total	
	No	%	No	%	N	%
<50	3	6.82	3	6.82	6	13.64
51-100	8	18.18	12	27.27	20	45.45
101-150	4	9.09	9	20.45	13	29.55
151-200	2	4.55	1	2.27	3	6.82
201-250	0	0.00	1	2.27	1	2.27
>250	1	2.27	0	0.00	1	2.27
Total	18	40.91	26	59.09	44	100.00

Figure: 10

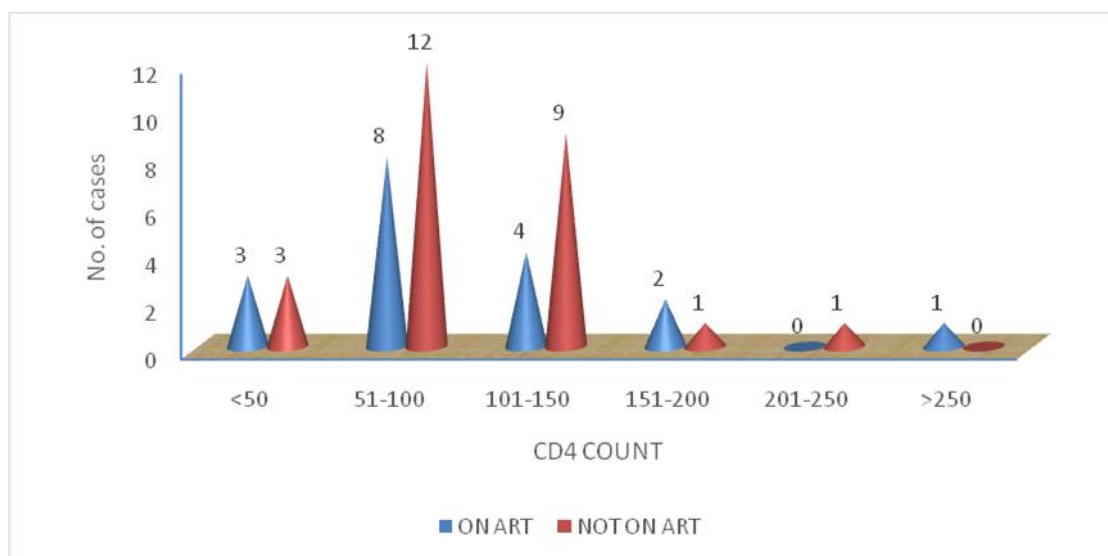


Table 10 showing CD4 counts. CD4 cell count was done in all 44 patients. Out of these 6 patients (13.6%) were having CD4 count <50 cells/mm (3 patients were taking ART and 3 were not taking ART). 20 patients (45%) had CD4 count between 51-100 ( 8 patients were on ART and 12 patients were not taking ART). 13 patients (29.5%) patients were having CD4 count

between 101-150 (4 were taking ART ,9 were not taking ART). 3 patients (6.82%) had CD4 count between 151-200 (2 were on ART,1 was not taking ART). 1 patient (2.27%) was having CD4 count between 201-250 and he was not taking ART. 1 patient (2.27%) patient was having CD4 count >250 and he was not taking ART.

Table no. 11 CT Head plain findings (n=23)

Abnormality	No. of Patients	Percentage
Hypodense area	9	39.13
SOLs	4	17.39
Normal	10	43.48
Total	23	100.00

Figure: 11

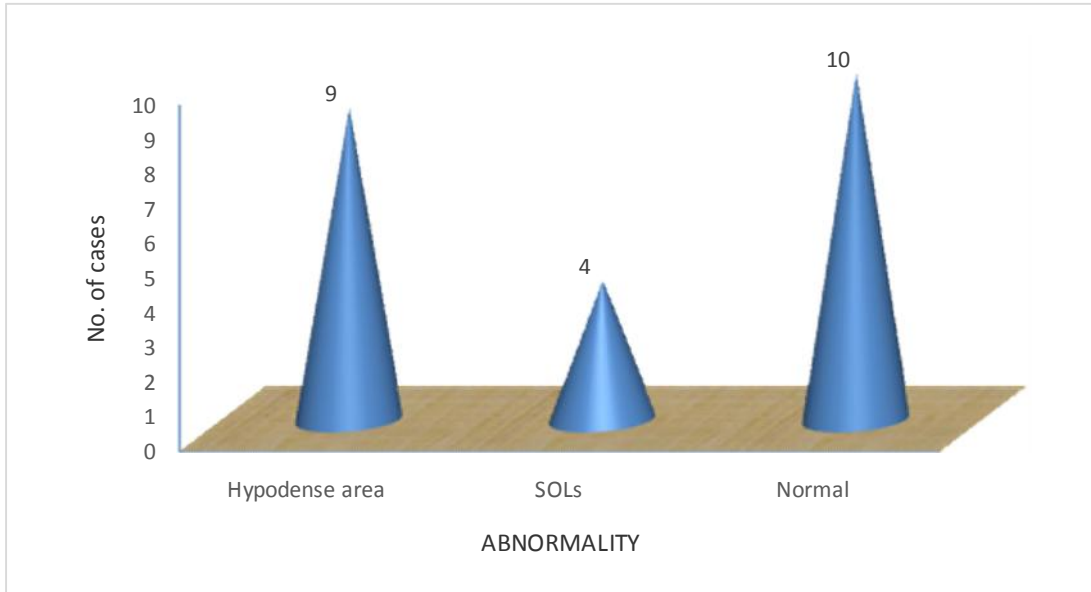


Table 11 showing NCCT head findings. Non contrast CT head was done in emergency in 23 patients. Hypodense area suggestive of infarcts was present in 9

patients (39.1%). 4 patients (17.39%) were having space occupying lesions. 10 patients (43.48%) were having normal CT head.

Table no. 12 MRI Brain (Contrast findings) (n=21)

Abnormality	No. of Patients	Percentage
Ring Enhancing lesions	5	23.81
Infarcts	7	33.33
SOLs	4	19.05
Meningeal enhancement	4	19.05
Multiple Haemorrhages	1	4.76
Total	21	100.00

Figure:12

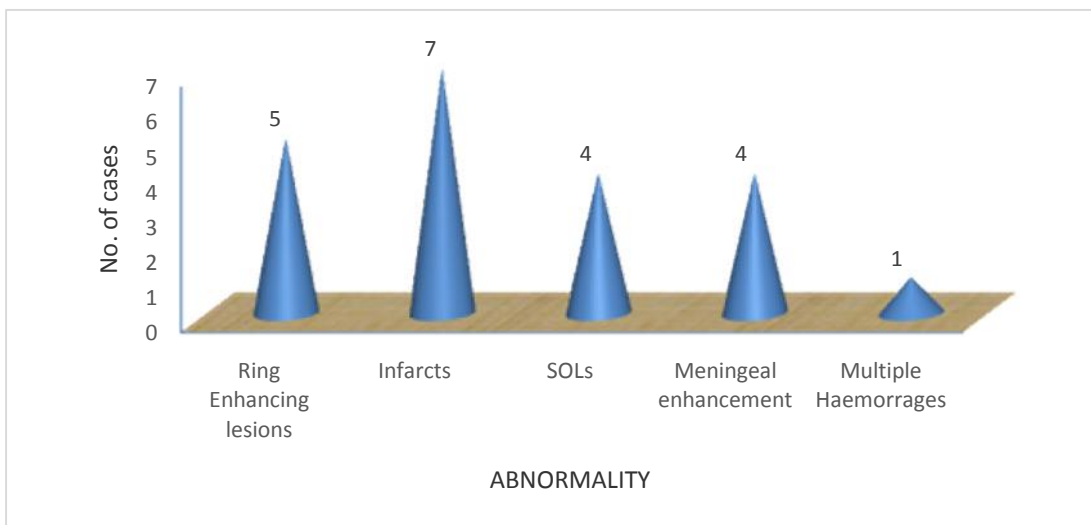


Table 12 showing MRI brain findings. MRI Brain was done in 21 patients. 7 patients (33.3%) were having infarcts followed by 5 patients (23.81) were having ring enhancing lesions. 4 patients (19.05%) were having space occupying lesions, out of these 2 were

having findings suggestive of lymphoma. 4 patients (19.05%) were having meningeal enhancement. 1 patient (4.76%) was having multiple haemorrhages in frontal parietal and temporal lobes.

Table no. 13 MRI Spine findings (n=3)

MRI Abnormality	No. of Patients	Percentage
HIV myelopathy	2	66.66
Sub-acute combined degeneration of Spinal cord	1	33.34
Total	3	100.0

Figure :13

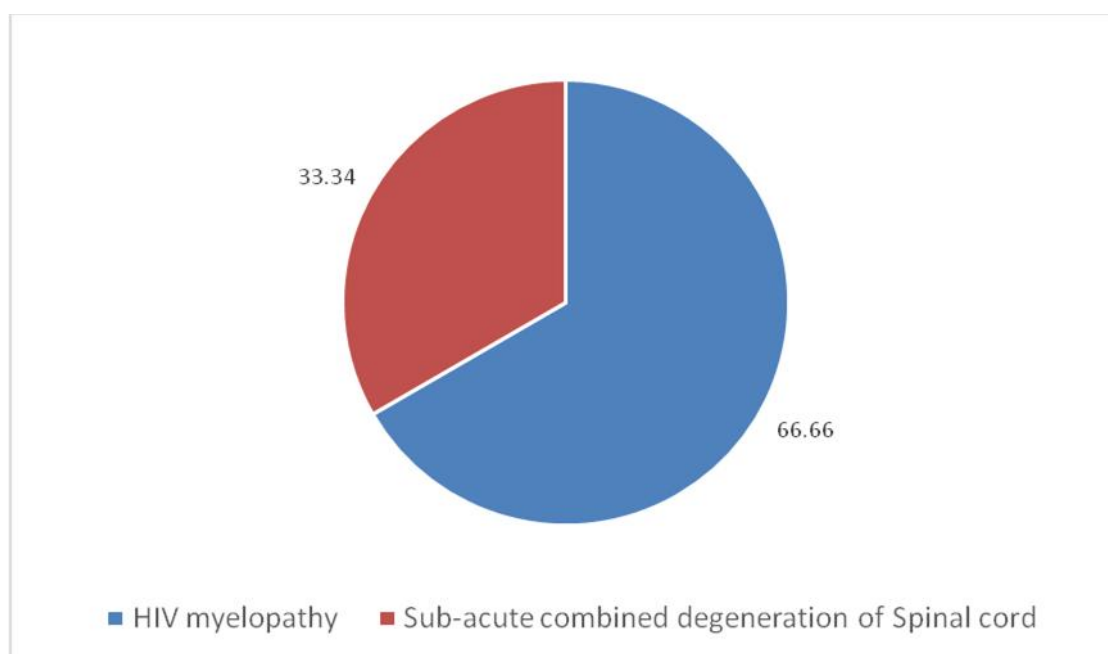


Table 13 showing MRI spine findings. MRI spine was done in 3 patients (6.81%). HIV myelopathy was

reported in 2 patients (66.6%) and one patient was having features suggestive of sub-acute combined degeneration of spinal cord.

Table no. 14 CSF Profile (n=26)

CSF Findings	No. of Patients	Percentage
Tubercular meningitis	16	61.53
Cryptococcal meningitis	7	26.92
Normal	3	11.53
Total	26	100

Figure: 14

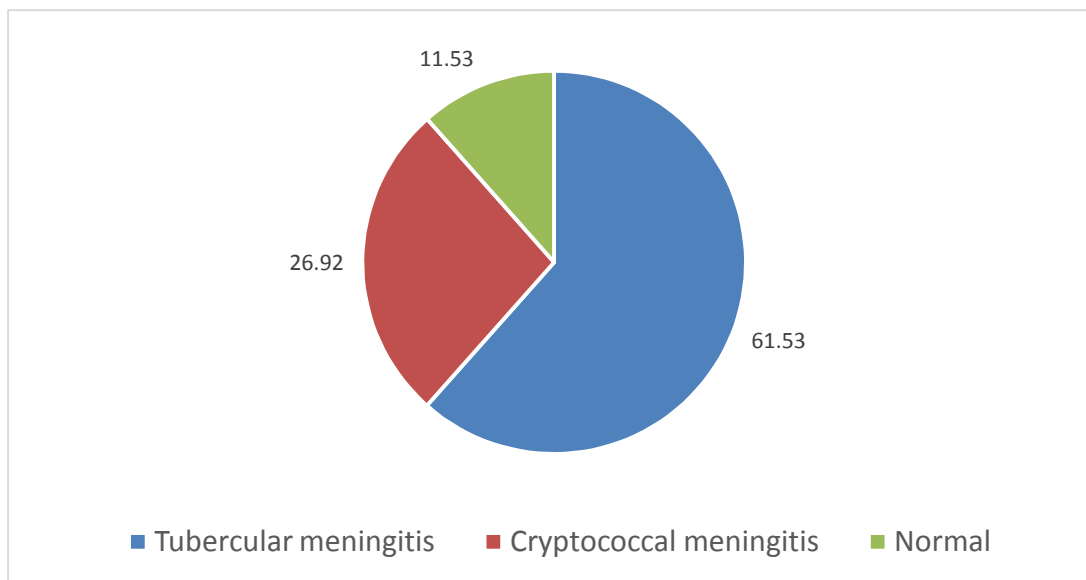


Table 14 showing CSF profile results. CSF profile was done in 26 patients. 16 patients (61.53%) had features suggestive of TB meningitis. 7 patients (26.92%) had

cryptococcal meningitis. 3 patients (11.53%) had normal findings.

Table no. 15 Opportunistic neurological infections (n=27)

Diagnosis	No. of Patients	Percentage
TBM	16	59.26
Cryptococcal meningitis	7	25.93
Toxoplasmosis	4	14.81
Total	27	100.00

Figure: 15

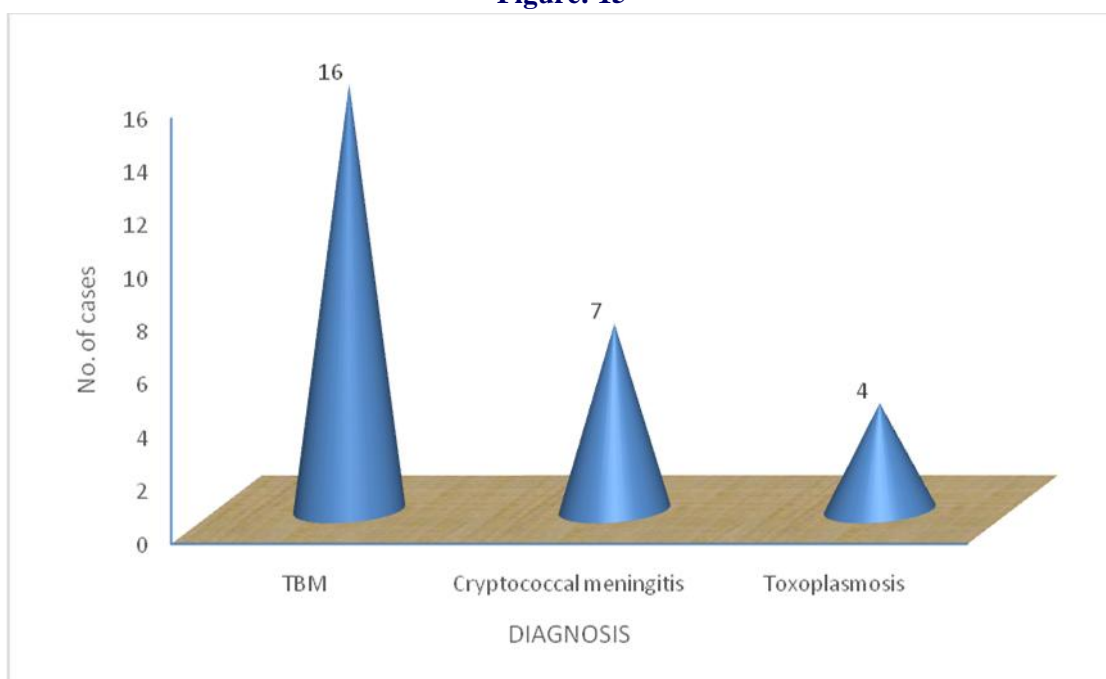


Table 15 showing distribution of opportunistic neurological manifestations. 27 patients (61.36%) were having opportunistic neurological infections. Out of these, tubercular meningitis was present in 16

patients (59.26%), cryptococcal meningitis in 7 patients (25.93%), toxoplasmosis was found in 4 patients (14.81%).

Table no. 16 Non-opportunistic infections related neurological manifestations (n=16)

Neurological diagnosis	No. of Patients	Percentage
Cerebral Infarcts	9	56.25
HIV myelopathy	2	12.50
Sub-acute degeneration of spinal cord	1	6.25
Peripheral Neuropathy	1	6.25
Sensory Ataxia	1	6.25
CNS Lymphoma	2	12.50
Total	16	100.00

Figure: 16

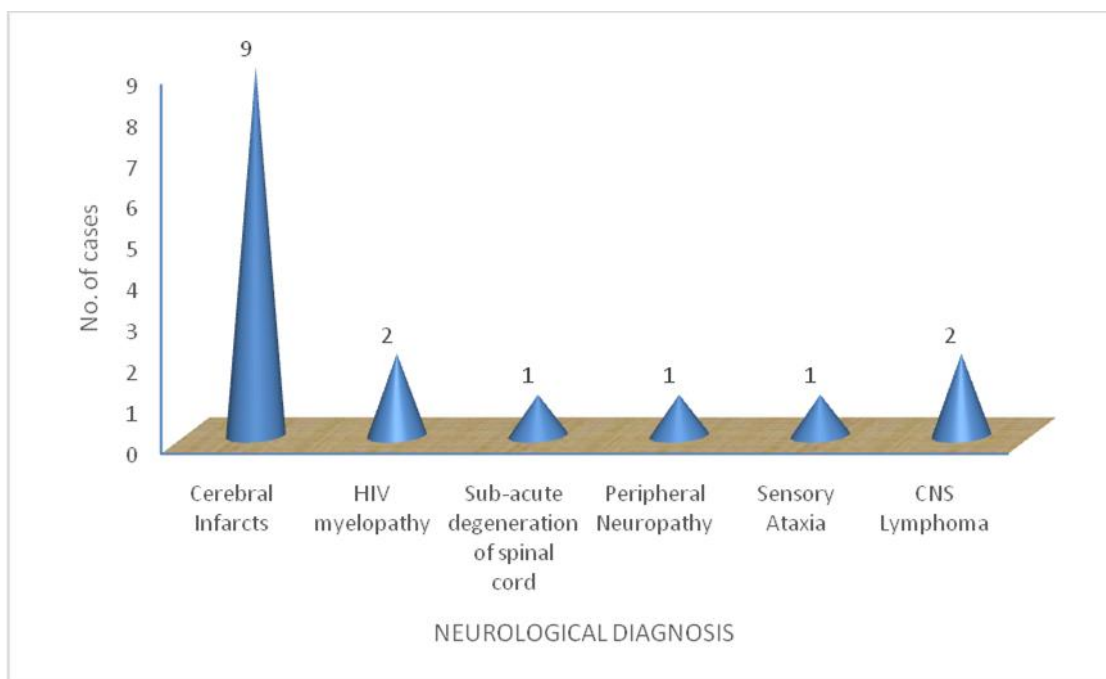
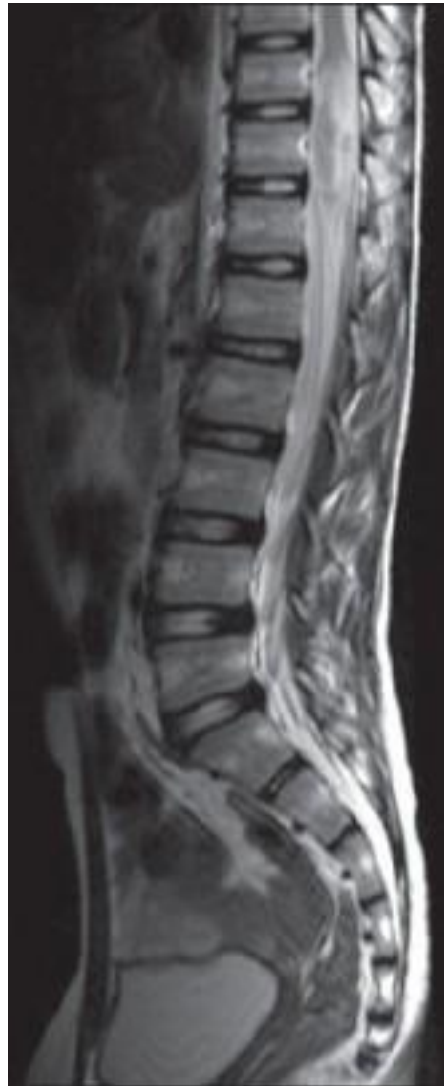

Table 16 showing Non-opportunistic infections related neurological manifestations. 16 patients (36.4%) were having non-opportunistic infections related neurological manifestations. Out of these 9 patients (56.25%) were having cerebral infarcts, 2 patients

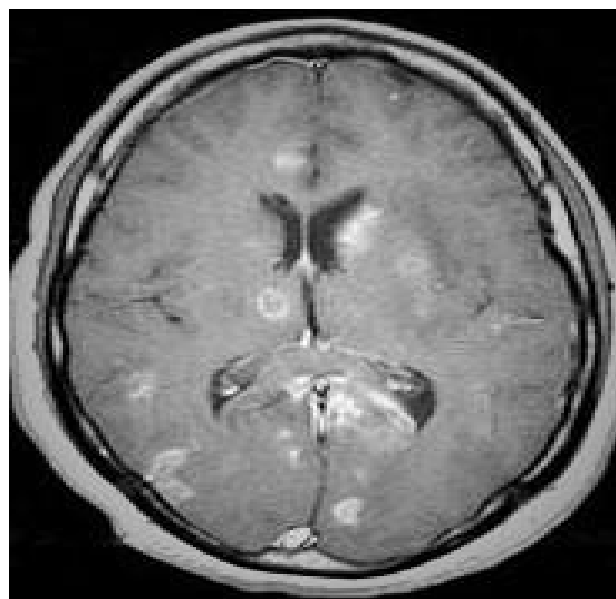
(12.5%) patients were having HIV myelopathy, 1 patient (6.25%) each had peripheral neuropathy, sensory ataxia and sub-acute combined degeneration of spinal cord. 2 patients (12.5%) had CNS lymphoma.

**Figure: 17**



Intramedullary tuberculoma with arachnoiditis. Heterogeneous hyperintensity is seen at the conus on T2W image

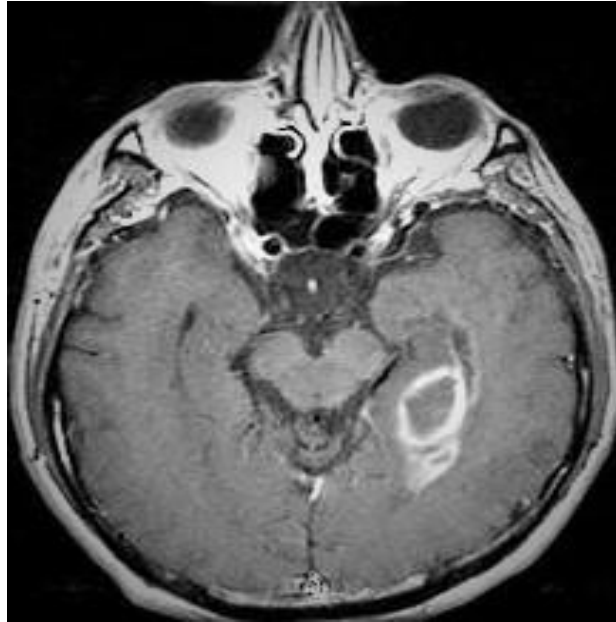**Figure: 18**



MRI of AIDS patient with toxoplasmosis. T1 weighted image obtained after the administration of

intravenous contrast demonstrates numerous enhancing lesions throughout the brain.

**Figure: 19**



MRI of AIDS patient with primary CNS lymphoma. T1 weighted image obtained after the administration of intravenous contrast demonstrates a ring-enhancing lesion in the medial left temporal lobe.

the age group of 31-40 years, which correlates with study by Gonogra-Rivera F et al from Mexico studied 149 patients; the average age of the patients was 33.8 years.<sup>10</sup>

## Discussion

At least 40% of HIV-infected patients develop neurological symptoms during the course of their illness. HIV infection is responsible for a large number of non opportunistic neurologic manifestations that occur across a large immune spectrum. During the early course of the disease, the polyclonal hypergammaglobulinemia induced by the virus results in demyelinating diseases of the CNS and peripheral nervous system (PNS), as the HIV infection progresses, the direct toxic effects of the virus unfold, directly damaging the CNS and PNS, resulting in clinical manifestations.<sup>9</sup> To the best of our knowledge, there has been no study regarding neurological manifestations in AIDS from punjab. We evaluated HIV patients from Amritsar district presented with neurological manifestations.

The neurological problem that occurs in HIV infected individual may be either primary to pathological process of HIV infection or secondary to opportunistic infection or neoplasm. In the present study, maximum incidence of neurological involvement was present in

Prevalence of male patients was more than female patients with neurological involvement. There were 28(63%) male and 16(36%) female patients in our study.

which is comparable to the study done by Solu MD et al having male ratio more than females (2.9:1).<sup>11</sup> In present study, the most common presenting symptoms were fever (59%). Most common neurological symptom was headache in 22 patients (50%), followed by meningeal irritation in 20 patients (45.4%) , features of altered sensorium in 19 patients (43.18%) , focal neurological deficit in 15 patients (34.05%) and seizures 4 patients (9.09%). Similarly studies done by Atilli et al and Rao CR et al showed that the most common neurological symptoms was headache in 70% patients which was attributed to raised ICT, altered sensorium in 46%, seizures in 8% patients and The most common manifestation was headache in 70% patients which was attributed to raised ICT, altered sensorium in 46%, seizures in 8% patients and neck stiffness was observed in 30% patients.<sup>12,13</sup>



Analysis of these clinical symptoms revealed that the most common cause of headache and altered sensorium was tuberculous meningitis (61%) followed by cryptococcal meningitis (29%) and toxoplasmosis (14%) which was comparable to a study done by Attili SV et al which also found the most common cause of headache to be tuberculous meningitis.<sup>12</sup>

In our study HIV induced primary neurological (non-opportunistic) illness were present in 16 (36%) cases, while secondary (opportunistic) neurological illness were present in 27 (61%) cases. This was comparable to the results revealed in the studies done by Solu MD et al<sup>11</sup> and Mansuri ZH et al<sup>13</sup> So, the opportunistic infections remain the leading cause of neurological manifestations in HIV.

The most common opportunistic neurological complication of HIV infection in our study was tuberculous meningitis in 16 (59.26%) patients, followed by cryptococcal (25%) and toxoplasmosis in (14%) cases. Our study was comparable with study by Sonkar SK et al showing meningitis was the most common neurological manifestation present in 29(67.44%) patients, Among the meningitis types, tubercular meningitis was most common type present in 21 (70.0%) cases, followed by cryptococcal in 7(23.3%) cases.<sup>14</sup>

Although, most common non-opportunistic complication is neuropathy<sup>11</sup> but in our study it was HIV related non-hemorrhagic infarcts in 9 (205%) cases. This might be due to small sample size and most of patients were not on ART. A hospital-based study in KwaZulu-Natal, South Africa, reported that the prevalence of HIV infection in a series of patients younger than 50 years who had had a stroke was 16%, similar to the prevalence of HIV in the general population of a similar age.<sup>15</sup> Our study was having little higher prevalence this might be due to small sample size.

Focal space occupying lesions in the brain can be due to toxoplasmosis, tuberculoma, progressive multifocal leukoencephalopathy (PML) and lymphomas.<sup>16</sup> Cryptococcomas usually occur in the context of cryptococcal meningitis. These space occupying lesions may manifest with seizures or focal deficits. In our study we had 4 (19.05%) patients with SOLs. 2 patients had primary lymphoma and 2 patients had toxoplasmosis. No case of PML was detected as its incidence is less in our settings. PML (progressive multifocal leukoencephalopathy) results from

infection with human polyoma virus (JC virus), developing in 4% of patients with AIDS.<sup>17</sup>

## Conclusion

The study revealed that a significant proportion of HIV/AIDS attending our institution had a varied spectrum of neurological manifestations. The neurological manifestations were more common in the young, males and in drivers, with sexual transmission being the commonest mode of HIV transmission in our study. Headache and altered sensorium were common neurological symptoms. Most common opportunistic neurological infections were tubercular meningitis followed by cryptococcal meningitis. Most common non-opportunistic neurological manifestations were cerebral infarcts and HIV myelopathy. Both CT and MRI were helpful in defining the neurological lesions. CSF was diagnostic for tubercular meningitis and cryptococcal meningitis. CD4 count strongly correlated with the presence of CNS manifestations. There must be a high index of suspicion for neurological manifestations in HIV patients presenting with neurological symptoms (e.g. headache and altered sensorium), as most of these opportunistic infections are treatable, which can reduce the morbidity and mortality.

## References

1. India HIV Estimation 2015 Technical Report 2015;1-43.
2. Hummer D, Rosenfeld JB, Pitlik SD. AIDS in the pre-AIDS era. *Reviews of Infectious Diseases* 1987;9:1102-8.
3. John TJ, Babu PG, Jayakumari H, Simoes EAF. Prevalence of HIV infection and risk groups in Tamil Nadu, India. *Lancet*. 1987;1:160-1.
4. <http://www.hindustantimes.com/punjab/world-aids-day-punjab-has-good-and-bad-news/story-e01S5XrNQPJoIEabTkVrTP.html>. Last assessed on 25/11/2017 at 10:15 A:M.
5. Longo DL, Kasper DL, Jameson JL, Fauci AS, Hauser LS, Loscalzo J. "Human Immunodeficiency Virus Disease: Aids and Related Disorders." *Harrison's Principle of Internal Medicine*. 19<sup>th</sup> ed, Vol2. McGraw Hill 2015;19(2):1227-41.
6. Levy RM, Bredesen DE, Rosenblum ML. Neurological manifestations of the acquired immunodeficiency syndrome (AIDS): experience at UCSF and review of the literature. *J Neurosurg*. 1985;62(4):475-95.



8. Venkataramana A, Pardo CA, McArthur JC, Kerr DA, Irani DN, Griffin JW. Immune reconstitution inflammatory syndrome in the CNS of HIV-infected patients. *Neurology* 2006; 67(3):383-8.
9. Deshpande AK, Patnaik MM. Nonopportunistic neurologic manifestations of the human immunodeficiency Virus: An Indian study. *J Int AIDS Soc.* 2005;7:2.
10. Gongora-Rivera F, Hamide A, Das AK. Neurological manifestations in HIV Disease. *J Trop Med Public Health.* 1996;27(4):686-91.
11. Solu MD, Dandge V, Kalra P, Prajapati R, Josh A. Clinical profile of HIV positive patients with neurological manifestations. *Guj Med J.* 2012;67(2):98-103.
12. Atilli SV, Gulati AK, Singh VP, Varma DV, Ray M, Sunder S et al. Neurological manifestations in HIV infection around Varnasi India. *Afr J Neurol Sci.* 2006;25:33-40.
13. Mansuri ZH, Kazi BC, Changadiya KHL. A study of clinical profile of neurological manifestations in

HIV positive patients with reference to CD4 Cell Count. *Int J Scientific Res.* 2014;3(10):329-31.

14. Sonkar SK, Gupta A, Atam V, Chaudhary SC, Tripathi AK, Sonkar GK. Clinical profile of neurological manifestation in Human Immunodeficiency Virus-positive patients. *North Am J Med Sci.* 2012;4:596-9.
15. Benjamin LA, Bryer A, Khoo S, Solomon T. HIV infection and stroke: current perspectives and future directions. *Lancet Neurol.* 2012;11(10): 878–90.
16. Clifford DB. Focal brain lesions in people with HIV. *Curr Treat Options Neurol* 1999;1:167-72.
17. Pavlovic D, Patera AC, Nyberg F, Gerber M, Liu M. Progressive multifocal leukoencephalopathy: current treatment options and future perspectives. *Therapeutic advances in neurological disorders* 2015;8(6):255-73.

<b>Access this Article in Online</b>	
	Website: <a href="http://www.darshanpublishers.com">www.darshanpublishers.com</a>
<b>Quick Response Code</b>	Subject: <b>Medicine</b>

**How to cite this article:**

Krishan Oberoi, Neeraj Joshi, Shiv Charan, NS Neki, Gaurav Joshi, Gagandeep Singh, Rajvir Singh, Akanksha Sandhu, Gurminder Multani, Gagandeep Shergill, Narender Meena, Deepali Kaushal, Inderjot Kaur, Priya Sharma, Deepak Rana. (2017). Assessment of neurological manifestations in HIV positive patients. *Int. J. Curr. Res. Biol. Med.* 2(11): 55-71.

DOI: <http://dx.doi.org/10.22192/ijrbm.2017.02.11.008>