
INTERNATIONAL JOURNAL OF CURRENT RESEARCH IN BIOLOGY AND MEDICINE

ISSN: 2455-944X

www.darshanpublishers.com

DOI:10.22192/ijcrbm

Volume 3, Issue 1 - 2018

Original Research Article

DOI: <http://dx.doi.org/10.22192/ijcrbm.2018.03.01.006>

Study of MRI in Lumbosacral pathologies

Inderpreet Kaur, **Neelam Gauba, ***Ramesh Chander, *VK Rampal, *****N.S. Neki**

*Junior Resident, **Professor, ***Professor & Head, ****Associate Professor, Dept. of Radiodiagnosis, Govt. Medical College, Amritsar, India

*****Professor & Head, Dept. of Medicine, Govt. Medical College, Amritsar, India

Corresponding Author: DR. Inderpreet Kaur, Junior Resident, Dept. of Radiodiagnosis, Govt. Medical College, Amritsar, India, 143001

E-mail: dr.ipkaur11@gmail.com

Abstract

Background: The patients of Lumbosacral pathologies most commonly present with complaint of low back pain. Low back pain (LBP) is the most prevalent musculoskeletal condition and the most common cause of disability. This study aimed to identify various lumbosacral pathologies.

Material and Methods: A cross-sectional study of 100 cases was carried out in the Department of Radiodiagnosis and Imaging, Govt. Medical College, Amritsar who were referred for MRI of lumbosacral spine for various reasons. MRI was done on Siemens Magnetom Aera 1.5 Tesla.

Results: The most common presenting complaint was found to be low back pain (91%) Out of 100 cases, 74 cases came out to be of LDD (lumbosacral disc degeneration) in the age group of 41-50 yrs of age, in patients of sedentary lifestyle with the maximum propensity at L4-L5 and L5-S1 levels with 78.37% and 72.97% respectively. Apart from LDD, other pathologies included tumours, infections, congenital lesions etc. Tumours included both primary and metastatic tumours. Among the infections, tubercular and pyogenic were found. The congenital lesions included spina bifida. One rare case of subcutaneous hydatid cyst was seen.

Conclusion: Although there are many aetiologies of low back pain, the majority of patients had nonspecific low back pain and LDD was the most common pathology among these patients and very few had other serious systemic aetiologies.

Keywords: Lumbosacral, Low back pain, MRI

Introduction

The patients of Lumbosacral pathologies most commonly present with complaint of low back pain. Low back pain (LBP) is the most prevalent musculoskeletal condition and the most common cause of disability in developed nations¹. LBP is equally a problem in the developing countries. Data on LBP in the developing countries is scanty, hence the need for the study. LBP has significant economic implications as it results in disability of the working population². In daily medical practice, most patients presenting with LBP may require immediate

diagnostic imaging when not responsive to conservative management³.

Experimental studies suggest that low back pain may originate from many spinal structures including ligaments, facet joints, vertebral periosteum, the paravertebral musculature and fascia, blood vessels, annulus fibrosus and spinal nerve roots. The most common are musculo-ligamentous injuries and age related degenerative processes in the intervertebral discs and facet joints. Other common problems include spinal stenosis and disc herniation⁴.

Conventional X-ray images have the drawback that potentially harmful radiation is employed, in addition to possessing a limited contrast resolution for diagnosis of various lumbosacral pathologies. An MRI study can present a greater abundance of morphologic details where pathologic relevance is unclear.

Lumbar disc degeneration occurs commonly in humans. There are a variety of factors that contribute to this condition. Some of the socio-demographic factors which have been said to play a role in the development of lumbar disc degeneration (LDD) include older age, female sex and sedentary lifestyle^{5,6}.

MRI patterns have been reported in various studies which showed other lumbosacral pathologies apart from lumbar disc degeneration. Results of these studies showed malignancy, infection, osteoporotic vertebral fracture, spondylitis, and cord tumours⁷. Early diagnosis of spinal infections will decrease morbidity in many cases. Although a clinical diagnosis of infections of the spine can sometimes be made in patients presenting with fever, elevated erythrocyte sedimentation rate and back pain, confirmation of the diagnosis is nearly always made on imaging studies. Intraspinal tumours may originate from the spinal cord, filum terminale, nerve roots, meninges, intraspinal vessels, sympathetic chain, or vertebrae. They can be benign or malignant, primary or secondary, and may result in serious morbidity. Intraspinal tumours are relatively uncommon lesions. However, these lesions can cause significant morbidity and can be associated with mortality as well. In establishing the differential diagnosis for a spinal lesion, location is the most important feature⁸. Once the lesion is localized, a differential diagnosis can be developed based on the site of tumour. Some lesions have characteristic MRI or radiographic features that may allow for a definitive diagnosis based on imaging studies alone⁹.

Spinal dysraphism includes wide spectrum of congenital disorders caused by incomplete or abnormal closure of neural tube during early embryogenesis. There is incomplete or absent fusion of midline spinal elements. These defects give rise to open or close neural tube defect. MRI provides an accurate and non-invasive method of evaluation of spinal dysraphism, making it the modality of choice. The excellent contrast resolution, wide field of view and multiplanar images allow evaluation of entire spinal cord, contents of back mass; detecting cord

tethering, associated syringomyelia, chiari malformations and other abnormalities¹⁰.

This study was focused on detection of various lumbosacral pathologies, their MRI patterns, so as to help in early diagnosis and thus planning optimal management.

Materials and Methods

This cross-sectional study was conducted in the Department of Radio diagnosis, Government Medical College, Amritsar. The study was conducted after approval from institutional thesis and ethical committee. All patients who underwent MRI of Lumbosacral spine for various reasons in the Department of Radio diagnosis and Imaging, Government Medical College, Amritsar were subjected for this study. In all the cases, written informed consent was taken from patients or his/ her attendants before entering the study. Out of these, 100 cases were selected. The study excluded patients having history of claustrophobia, who had metallic implant insertion, cardiac pacemakers and metallic foreign body in situ, cases where scanning was not possible due to poor general conditions and where MRI was contraindicated.

Examination technique and scanning protocols:

MRI was done on SIEMENS MAGNETOM AERA 1.5 TESLA. Appropriate MR sequences and multiplanar imaging was performed for every patient using following sequences.

Localizer sequence conventional spin echo.

Axial and sagittal T1 images

Axial, sagittal and coronal T2 images

Sagittal, STIR, T1 FS

Coronal TIRM T2 images

Contrast study (Gadolinium) was included in the study as and when required

Data Analysis: Proportion study

Results

The age range of patients was found from 8 years to 85 years and the peak range of age distribution was found between 31-50 years i.e. 45% of all cases. There were 48 males and 52 females. Thus the study sample consisted of 48% males and 52% females. The most common presenting complaint was found to be low back pain (LBP) in 91% of the cases followed by radiating pain in 58% of the cases. It was found that LDD (lumbosacral disc degeneration) is the most common pathology in lumbosacral spine i.e. 74% of the cases. It was found that out of 74 cases that were diagnosed as LDD on MRI, 41 patients were females and 33 males with a slightly higher incidence in females i.e. 55.41% as compared to males i.e. 44.59%. The age range of patients who were diagnosed as LDD was found from 22 years to 85 years and the peak range of age distribution was found between 41-50 yrs of age i.e. 29.72%. It was found that many patients had involvement of multiple disc levels with the maximum propensity at L4-L5 and L5-S1 disc levels with 78.37% and 72.97% respectively. It was found that LDD is more common in those having predominantly sedentary lifestyle which included office workers i.e. 29.72% cases followed by housewives being 27.02%. There were total of 74 cases of LDD. It was seen that disc desiccation was present in 40 cases (54.05%), disc bulge was seen in 56 cases (75.67%). There were 6 cases of disc protrusion, 12 cases of disc extrusion and 7 cases of disc sequestration with 8.10%, 16.21% and 9.45% respectively. Out of 74 cases, 44 cases (59.45%) showed Osteophytes. Facet joint hypertrophy was seen in 14 cases (18.91%). Ligamentum flavum

hypertrophy was seen in 20 cases (27.02%). Both Spondylolisthesis and end plate (modic) changes were seen in 8 cases (10.81%). The indentation/compression of thecal sac was seen in 43 cases (58.10%). The compression of neural foramina was seen in 45 cases (60.81%). Spinal canal stenosis was least common seen, in only 1 case. The disc bulge and disc desiccation was the most common MRI pattern with 75.67% and 54.05% respectively. Apart from these findings, Osteophytes were seen commonly in about 59.45% of all the cases of LDD. The most common complications of LDD seen were compression of neural foramina in 60.81% cases and indentation/compression of thecal sac in 58.10% cases.

Out of 100 cases 6 were found to be of infectious aetiology with 4 being Tubercular and 2 being pyogenic and were seen in the upper lumbar spine i.e. L1-L3 level. Out of 100 cases 8 patients were diagnosed with tumours, of there, 4 cases were of metastasis. Primary tumours of the lumbar spine were found to be rare with the most common being haemangioma. As very few cases of tumours were reported, so no inference can be drawn. Out of 100 cases, 2 cases showed only straightening of the spine with no other pathology detected and 1 rare case of Hydatid cyst in the subcutaneous tissue of lumbosacral spine was seen. Out of 100 cases, 3 cases were of congenital lesions where 2 cases showed features of spina bifida with lipomyelomeningocele and one case was of spina bifida with dermal sinus tract.

MAIN PRESENTING COMPLAINT (Many patients had more than 1 complaint) (n=100)

PRESENTING COMPLAINT	TOTAL	PERCENTAGE
LBP	91	91.00%
RADIATING PAIN	58	58.00%
INABILITY TO WALK	19	19.00%
LS SWELLING	18	18.00%
H/O TRAUMA	12	12.00%

**PERCENTAGE OF PROBABLE DIAGNOSIS OF LUMBOSACRAL PATHOLOGIES
ON MRI (n=100)**

PROBABLE DIAGNOSIS	NO. OF CASES (n=100)	PERCENTAGE %
LDD	74	74.00%
FRACTURE VERTEBRAE	6	6.00%
INFECTIONS	6	6.00%
CONGENITAL	3	3.00%
TUMOURS	8	8.00%
OTHERS	3	3.00%

**FREQUENCY OF SITE OF LESIONS IN LDD
(Many patients had multiple sites of involvement) (n=74)**

SITE OF LESIONS	FREQUENCY	PERCENTAGE
L1-L2	05	6.75%
L2-L3	14	18.91%
L3-L4	27	36.48%
L4-L5	58	78.37%
L5-S1	54	72.97%

LDD IN DIFFERENT OCCUPATIONS (n=74)

OCCUPATION	NO. OF CASES	PERCENTAGE
Office worker	22	29.72%
House wife	20	27.02%
Student	10	13.51%
Labourer	08	10.81%
Farmer	04	5.40%
Others (unemployed, retired, businessman)	10	13.51%

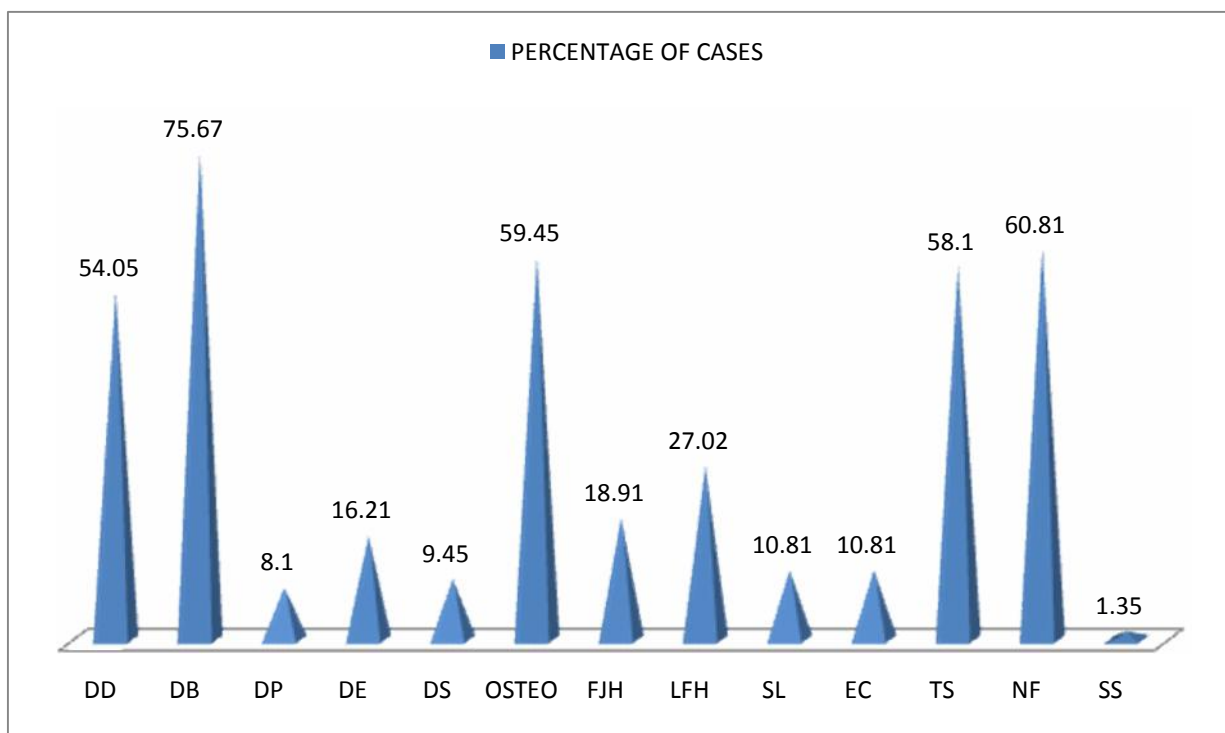
**MRI FINDINGS IN LDD
(A patient can have multiple findings) (n=74)**

MRI FINDINGS	NO. OF CASES	PERCENTAGE
Disc desiccation	40	54.05 %
Disc bulge	56	75.67 %
Disc protrusion	6	8.10 %
Disc extrusion	12	16.21 %
Disc sequestration	7	9.45 %
Osteophytes	44	59.45 %
Facet joint hypertrophy	14	18.91 %
Ligament flavum hypertrophy	20	27.02 %
Spondylolisthesis	8	10.81 %
Endplate (modic) changes	8	10.81 %
Indentation/ compression of thecal sac	43	58.10 %
Compression of neural foramina	45	60.81 %
Spinal canal stenosis	1	1.35 %

CASES OTHER THAN LDD

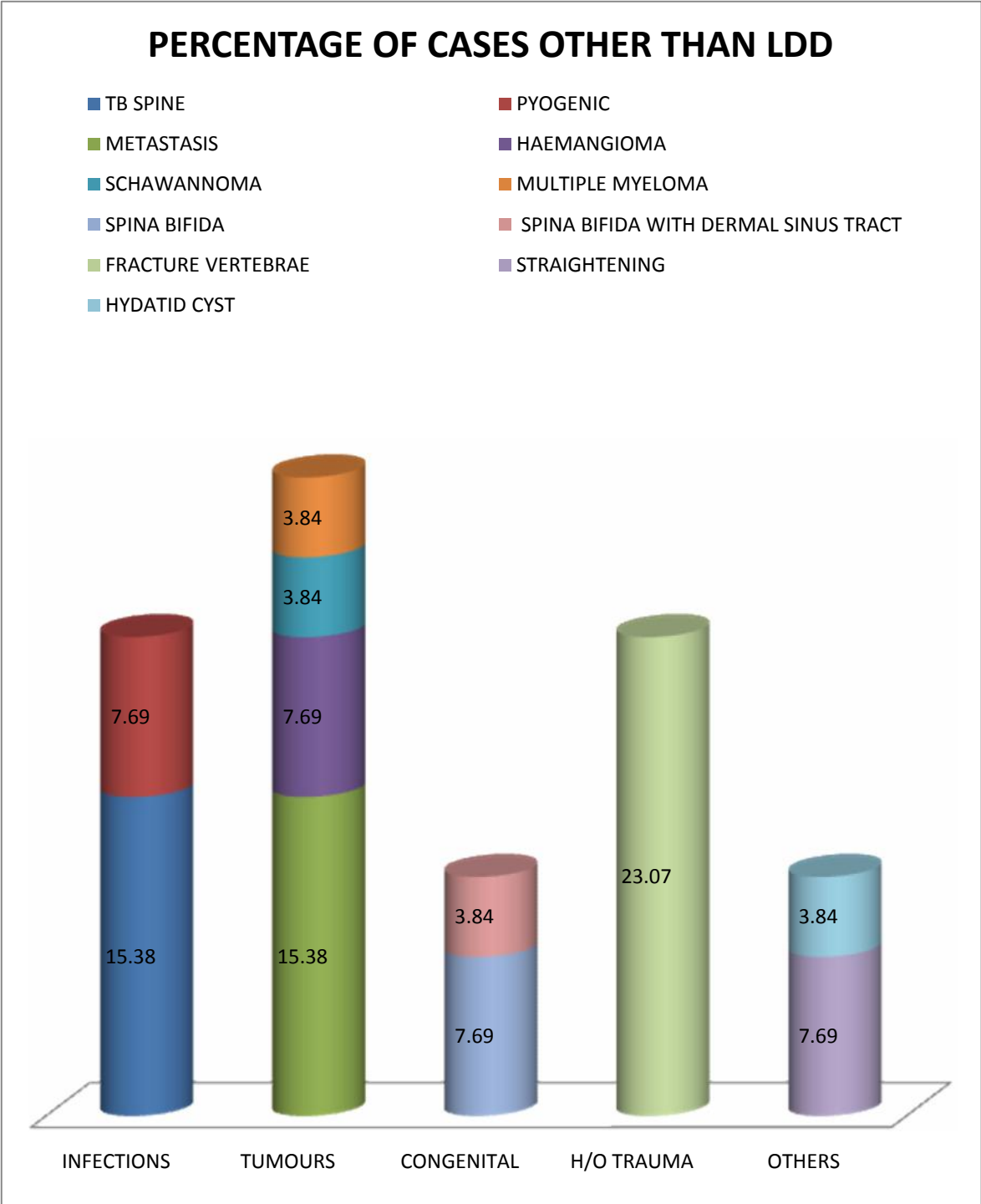
CASES	NO.	PERCENTAGE
INFECTIONS:		
• TB SPINE	4	15.38 %
• PYOGENIC	2	7.69 %
TUMOURS:		
• METASTASIS	4	15.38 %
• HAEMANGIOMA	2	7.69 %
• MULTIPLE MYELOMA	1	3.84 %
• SCHWANNOMA	1	3.84 %
CONGENITAL:		
• SPINA BIFIDA WITH LIPOMYELOMENINGOCELE	2	7.69 %
• SPINA BIFIDA WITH DERMAL SINUS TRACT	1	3.84 %
FRACTURES	6	23.07 %
OTHERS:		
• STRAIGHTENING OF SPINE	2	7.69 %
• HYDATID CYST	1	3.84 %

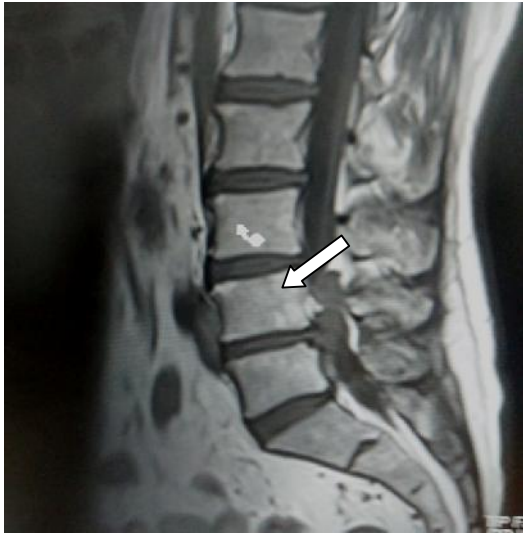MRI FINDINGS IN LDD



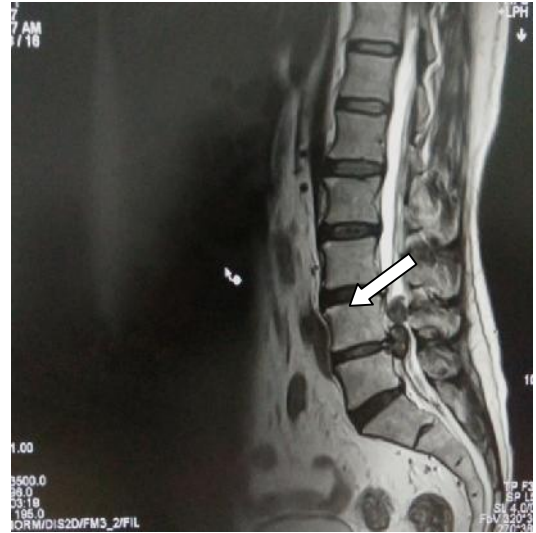DD: Disc desiccation; DB: Disc bulge; DP: Disc protrusion; DE: Disc extrusion; DS: Disc sequestration; OSTEO: Osteophytes; FJH: Facet joint hypertrophy; LFH: Ligamentum flavum hypertrophy; SL: Spondylolisthesis; EC: Endplate (modic) changes; TS: Indentation/compression of thecal sac; NF: Compression of neural foramina; SS: Spinal canal stenosis

CASES OTHER THAN LDD



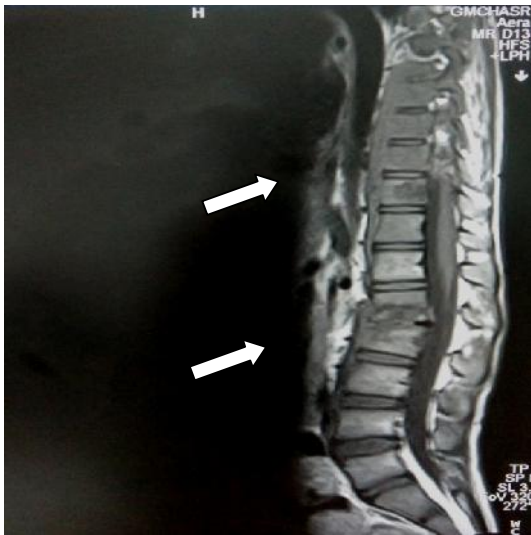

Sagittal T1W

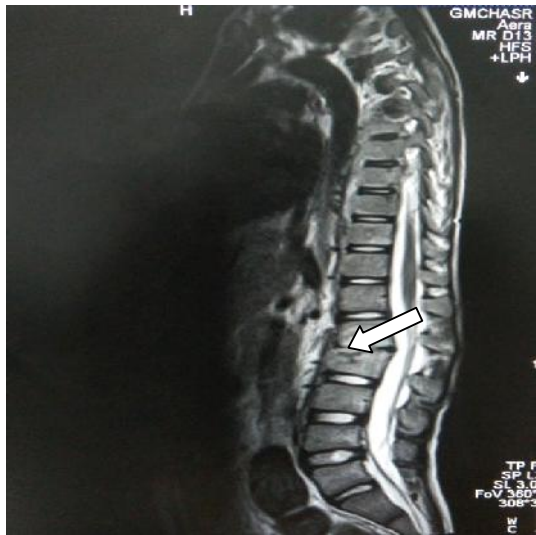

Sagittal T2W

LDD: Disc dessicative changes at multiple levels, narrow based disc extrusion and sequestration at the level of L4-L5 with migration of some of the extruded disc material cranially.

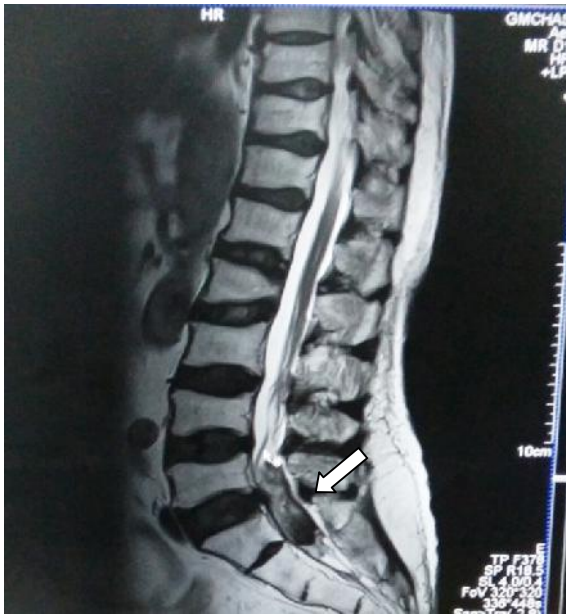

Sagittal T1W

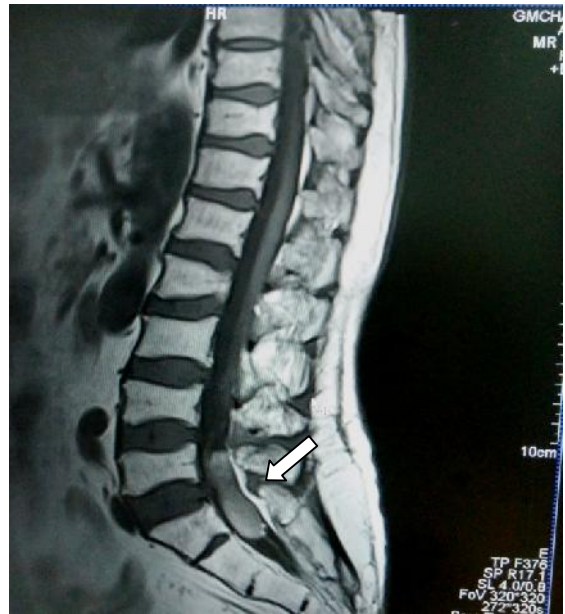

Sagittal T2W

Tuberculous spondylodiscitis: Destruction of the bodies of L1,L2 vertebrae and intervening disc with formation of acute angulation (Gibbus) at this level.

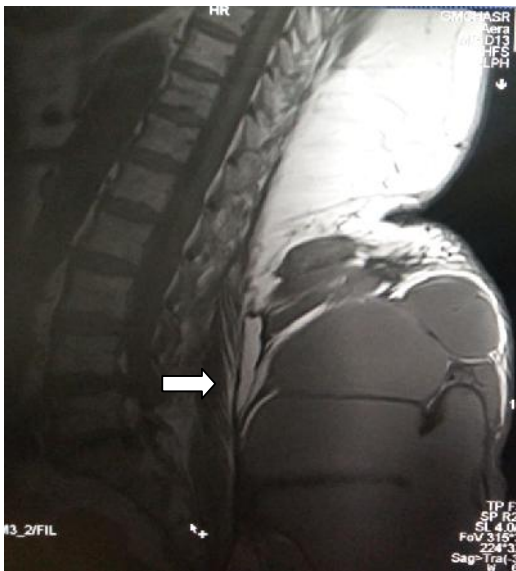


Sagittal T2W

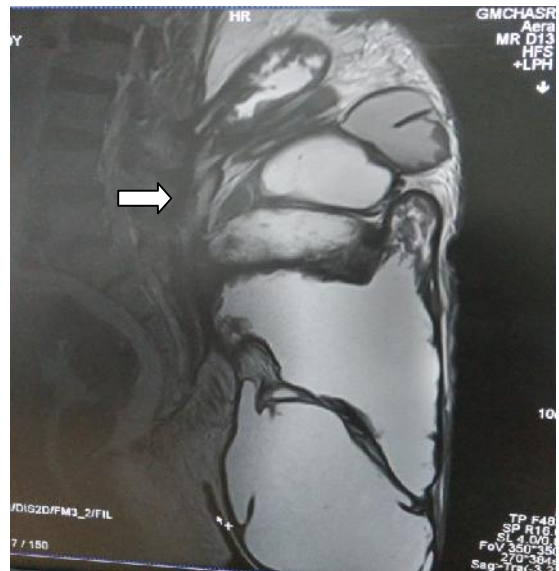

Sagittal T1W

Shwannoma: A heterogenous sausage shaped intradural extramedullary mass at the level of L5-S1.



Sagittal T1W



Sagittal T2W

Subcutaneous hydatid cyst: A large well defined multiloculated cystic mass with daughter cysts within it, is seen in the subcutaneous tissue.

Discussion

In this study, the age range of patients was found from 8 years to 85 years and the peak range of age distribution was found between 31-50 yrs of age i.e. 45% of all cases. Out of 100 patients, the study sample consisted of 48 males and 52 females. The main presenting complaint for which the patients were referred for MRI of lumbosacral spine was found to be low back pain (LBP) in 91% of the cases followed by radiating pain in 58% of the cases. In a study conducted by Biluts et al, pain, numbness and neurologic claudication were the three most common presenting symptoms occurring in 337(92.5%), 232 (63.7.6%) and 111 (30.5%) respectively in patients who were referred for MRI¹¹. These results were quite comparable to our study where low back pain followed by radiating pain was the most common complaint. The review of MRI patterns in our study established lumbar disc degeneration as the most common disease seen in 74 cases i.e. (74%). Other less frequently encountered but still significant patterns included: tumours 8%, infections 6%, fracture vertebrae 6%, congenital 3% and other causes 3%. In a study conducted by Juliette et al, it was found that Lumbar disc degeneration (LDD) was common (80%) in patients of low back pain¹². In a study conducted by Younis et al, in Lahore, on 170 patients mainly yielded findings of degenerative disc disease with other abnormalities like infective, inflammatory, neoplastic or congenital anomalies of the spine were excluded¹³. MRI patterns have been reported by McNally et al, in 1000 patients with non-traumatic LBP without radiculopathy. Results of their study showed that malignancy, infection, osteoporotic vertebral fracture, spondylitis, pars defects and cord tumours were detected in 20%. Their study detected neoplasms in 8% but excluded benign neoplasms like vertebral haemangioma and did not focus on the individual prevalence of each disease pattern⁷. In our study, it was found that out of 74 cases that were diagnosed as LDD on MRI, 41 patients were females and 33 males with a slightly higher incidence in females i.e. 55.41% as compared to males i.e. 44.59%. A study carried out in Nigeria yielded 40.9% males and 59.1% females with M: F (1:1.4). These findings likewise showed that more females were affected than males, a fact that can be attributed to the type of population sampled. The Nigerian study by Igbinedion et al, found that gender was not significantly associated with LBP¹⁴. In our study group age range of patients who were diagnosed as LDD was found from

22 years to 85 years. A prospective study completed by Makino H et al in the year 2017, revealed that 31% of the young adult subjects already had disc degeneration in 20's (time of first MRI) and the disc degeneration rapidly progressed in these subjects¹⁵. The peak range of age distribution was found between 41-50 years of age i.e. 29.72%. As per study done by *KW Ongeti et al*, LDD was commonest in the 31 – 50 year age group with mean age of 40.90±13.80 years, (range between 11- 85 years)¹⁶. In a study conducted by Juliette et al, the median age was 47 years and mean age was 47.32 ±14 years¹². In Cameroon, study done by Uduma et al, on 48 patients, it was found that the highest number of studied cases belonged to 50-59 year age range with 31.25% and the second highest studied range was 40-49years (29%)¹⁷. The findings in our study showed that many patients had involvement of multiple disc levels with the maximum propensity at L4-L5 and L5-S1 disc levels with 78.37% and 72.97% respectively. In a study conducted by Biluts et al, Lumbar disc degeneration was most frequently seen at L4-L5 level in 309 (54.5%) patients and both L4-L5 and L5-S1 together accounted for 79.1% of the disc displacements¹¹. In a study conducted by Juliette et al, the patients who had LDD, lesions were commonly seen at L4/L5 and L5/S1 levels¹². These findings are quite comparable to our study. In our study, disc bulge and disc desiccation were the most common MRI pattern with 75.67% and 54.05% respectively. Apart from these findings, Osteophytes were seen commonly in about 59.45% of all the cases of LDD. The most common complications of LDD seen were compression of neural foramina in 60.81% cases and indentation/compression of thecal sac in 58.10% cases. In a study done by Juliette et al, 65.41% bulges and 23.24% herniations (62.79% broad based, 6.98% extrusions, 30.23% protrusions) were reported. Nerve root compression was the most common complication¹². In our study, it was found that LDD is more common in those having predominantly sedentary lifestyle which included office workers i.e. 29.72% cases followed by housewives being 27.02%. The relationship between the degree of lumbar lordosis and chronic low back pain (LBP) has long been speculated. It is postulated that prolonged sitting and sedentary lifestyle might change the degree of lumbar lordosis and cause LBP¹⁸. In our study, out of 100 cases 6 were found to be of infectious aetiology with 4 being Tubercular and 2 being pyogenic.

Spondylodiscitis remains rare but its incidence is rising, due to an increasingly susceptible population and the availability of more effective diagnostic tools. A high index of suspicion is needed for prompt diagnosis to ensure improved long-term outcomes¹⁹. In our study, out of 100 cases, 8 patients were diagnosed with tumours. Out of these 8, there were 4 cases of metastasis, so metastasis was the most common amongst the lumbosacral spine neoplastic lesions. Primary tumours of the lumbosacral spine were found to be rare with the most common primary tumour being haemangioma. As very few cases of tumours were reported, so no inference could be drawn. Imaging modalities can provide useful tools for narrowing the differential diagnosis and directing biopsy²⁰. Out of 100 cases, 3 cases of congenital lesions of lumbosacral spine were found. All the three cases had spina bifida with associated anomalies. A systematic approach and correlation with neuroradiological, clinical and developmental data helps in making the correct diagnosis²¹. In our study, we found one rare case of Hydatid cyst in subcutaneous tissue of lumbosacral region. MRI of the patient showed a large well defined multiloculated cystic mass with daughter cysts within in the subcutaneous tissue. In a study conducted by Alti et al, in the year 2014, reported a rare primary subcutaneous hydatid cyst which was detected over the thoracic spine. He further concluded that diagnosis of hydatid disease in organs other than the liver or lung sometimes is not straightforward and causes delay in treatment. In endemic areas, hydatid disease should be taken into consideration for differential diagnosis when a cystic lesion is identified in any organ of the body²².

Summary

The results obtained were compared and relevant conclusions were drawn. The age range of all the patients was found from 8 years to 85 years and the peak range of age distribution was found between 31-50 yrs of age i.e. 45% of all cases. The most common presenting complaint was found to be low back pain (LBP) in 91% of the cases followed by radiating pain in 58% of the cases. It was found that LDD (lumbosacral disc degeneration) is the most common pathology in lumbosacral spine i.e. 74% of the cases. It was found that out of 74 cases that were diagnosed as LDD on MRI, 41 patients were females and 33 males with a slightly higher incidence in females i.e. 55.41% as compared to males i.e. 44.59%.

The age range of patients who were diagnosed as LDD was found from 22 years to 85 years and the peak range of age distribution was found between 41-50 yrs of age i.e. 29.72%. It was found that many patients had involvement of multiple disc levels with the maximum propensity at L4-L5 and L5-S1 disc levels with 78.37% and 72.97% respectively and also more common in those having predominantly sedentary lifestyle which included office workers i.e. 29.72% cases followed by housewives being 27.02%. The disc bulge and disc desiccation were the most common MRI pattern amongst patients of LDD with 75.67% and 54.05% respectively. Apart from these findings, Osteophytes were seen commonly in about 59.45% of all the cases of LDD. The most common complications of LDD seen were compression of neural foramina in 60.81% cases and indentation/compression of thecal sac in 58.10% cases. Out of 100 cases 6 were found to be of infectious aetiology with 4 being Tubercular and 2 being pyogenic. Out of 100 cases 8 patients were diagnosed with tumours. Out of these 8, there were 4 cases of metastasis so metastasis was the most common lumbosacral spine neoplastic lesion. Primary tumours of the lumbosacral spine were found to be rare with the most common primary tumour being haemangioma. Out of 100 cases, 2 cases showed only straightening of the spine with no other pathology detected and 1 rare case of Hydatid cyst in the subcutaneous tissue of lumbosacral spine was seen. Out of 100 cases, 3 cases of congenital lesions of lumbosacral spine were found. All the three cases had spina bifida with associated anomalies.

Conclusion

Although there are many aetiologies of low back pain as it was most common complaint for which the patients were referred for MRI, the majority of patients had nonspecific low back pain and LDD was the most common pathology among these patients and very few had other serious systemic aetiologies. Plain radiograph can be helpful, but MRI is the standard imaging modality of choice. MRI is generally considered the best initial exam for most patients with low back pain who require advanced imaging. It provides axial as well as sagittal views which can demonstrate normal and pathologic discs, ligaments, nerve roots, epidural fat, as well as the shape and size of the spinal canal, helps in detection of spinal infection and malignancy, thus planning the optimal management.

Source of funding: Nil

Conflict of interest: None declared

References

1. Woolf AD, Pfleger B. Burden of major musculoskeletal conditions. *Bulletin of the World Health Organization* 2003;81(9):646-56.
2. Katz RT. Impairment and disability rating in low back pain. *Clinics in Occupational and Environmental Medicine* 2006;5(3):719-40.
3. Patel AT, Ogle AA. Diagnosis and management of acute low back pain. *Am Fam Physician* 2000;61(6):1779-86.
4. Deyo RA, Weinstein JN. Low Back Pain. *New England Journal of Medicine* 2001;344(5):363-70.
5. Rosecrance J, Rodgers G, Merlino L. Low back pain and musculoskeletal symptoms among Kansas farmers. *American Journal of Industrial Medicine* 2006;49(7):547-56.
6. Yong PY, Alias NN, Shuaib IL. Correlation of Clinical Presentation, Radiography, and Magnetic Resonance Imaging for Low Back Pain-a Preliminary Survey. *Journal-Hong Kong College of Radiologists* 2003;6:144-51.
7. McNally EG, Wilson DJ, Ostlere SJ. Limited magnetic resonance imaging in low back pain instead of plain radiographs: experience with first 1000 cases. *Clinical Radiology* 2001;56(11):922-5.
8. Granada AM. A Comprehensive Review of Intraspinous tumours: Diagnostic, classification and radio-pathologic correlation. *European Congress of Radiology* 2013:1-50.
9. Gebauer GP, Farjoodi P, Sciubba DM, Gokaslan ZL, Riley III LH, Wasserman BA et al. Magnetic resonance imaging of spine tumours: classification, differential diagnosis, and spectrum of disease. *JBJS* 2008;90:146-62.
10. Tortori-Donati P, Rossi A, Biancheri R, Cama A. Magnetic resonance imaging of spinal dysraphism. *Topics in Magnetic Resonance Imaging* 2001;12(6):375-409.
11. Biluts H, Munie T, Abebe M. Review of lumbar disc diseases at Tikur Anbessa Hospital. *Ethiopian Medical Journal* 2012;50(1):57-65.
12. Orege JA, Abuya JM, Elias GD. Common magnetic resonance imaging (MRI) patterns in patients with low back pain in Eldoret, Kenya. *J Sci Innov Res.* 2013;2:260-79.
13. Younis F, Shahzad R, RasoolF. Correlation of Magnetic Resonance Patterns of Lumbar Disc Disease with Clinical Symptomatology of Patients. *Annals* 2011;17(1):41-7.
14. Igbinedion BE, Akhigbe A. Correlations of radiographic findings in patients with low back pain. *Journal of the Nigeria Medical Association* 2011;52(1):28.
15. Makino H, Kawaguchi Y, Seki S, Nakano M, Yasuda T, Suzuki K et al. Lumbar disc degeneration progression in young women in their 20's: A prospective ten-year follow up. *Journal of Orthopaedic Science* 2017;4:635-40.
16. Ongeti KW, Ogeng'o J, Gakuu LN, Saidi H, Pulei A. Prolapsed Intervertebral Disc in an African Population: Kenyan Experience. *East African Orthopaedic Journal* 2012;6(1):12-5.
17. Uduma DF, Ongolo P, Assam G, Fokam P, Motah M. Evaluation of pattern of magnetic resonance images of lumbo-sacral spine in Cameroon-a pioneer study. *Global Journal of Medical Research* 2011;11(2):1.
18. Nourbakhsh MR, Moussavi SJ, Salavati M. Effects of lifestyle and work-related physical activity on the degree of lumbar lordosis and chronic low back pain in a Middle East population. *Clinical Spine Surgery* 2001;14(4):283-92.
19. Gouliouris T, Aliyu SH, Brown NM. Spondylodiscitis: update on diagnosis and management. *Journal of Antimicrobial Chemotherapy* 2010;65 (suppl 3):11-24.
20. Garcia DA, Aivazoglou LU, Garcia LA, Ferreira FB, França SM, Guimarães JB et al. Diagnostic Imaging of Primary Bone Tumours of the Spine *Current Radiology Reports* 2017;5(7):30.

21. Kumar J, Afsal M, Garg A. Imaging spectrum of spinal dysraphism on magnetic resonance: A pictorial review. World Journal of Radiology 2017;9(4):178.
22. Altı TO, Kist H, ve Literatürün BO, Geçirilmesi G. Primary subcutaneous hydatid cyst over thoracic spine: a case report and review of the literature. Türkiye Parazitolojisi Dergisi 2014;38:264-9.

Access this Article in Online	
	Website: www.darshanpublishers.com
	Subject: Medical Sciences
Quick Response Code	

How to cite this article:

Inderpreet Kaur, Neelam Gauba, Ramesh Chander, K Rampal, N.S. Neki. (2018). Study of MRI in Lumbosacral pathologies. Int. J. Curr. Res. Biol. Med. 3(1): 44-55.

DOI: <http://dx.doi.org/10.22192/ijrbm.2018.03.01.006>